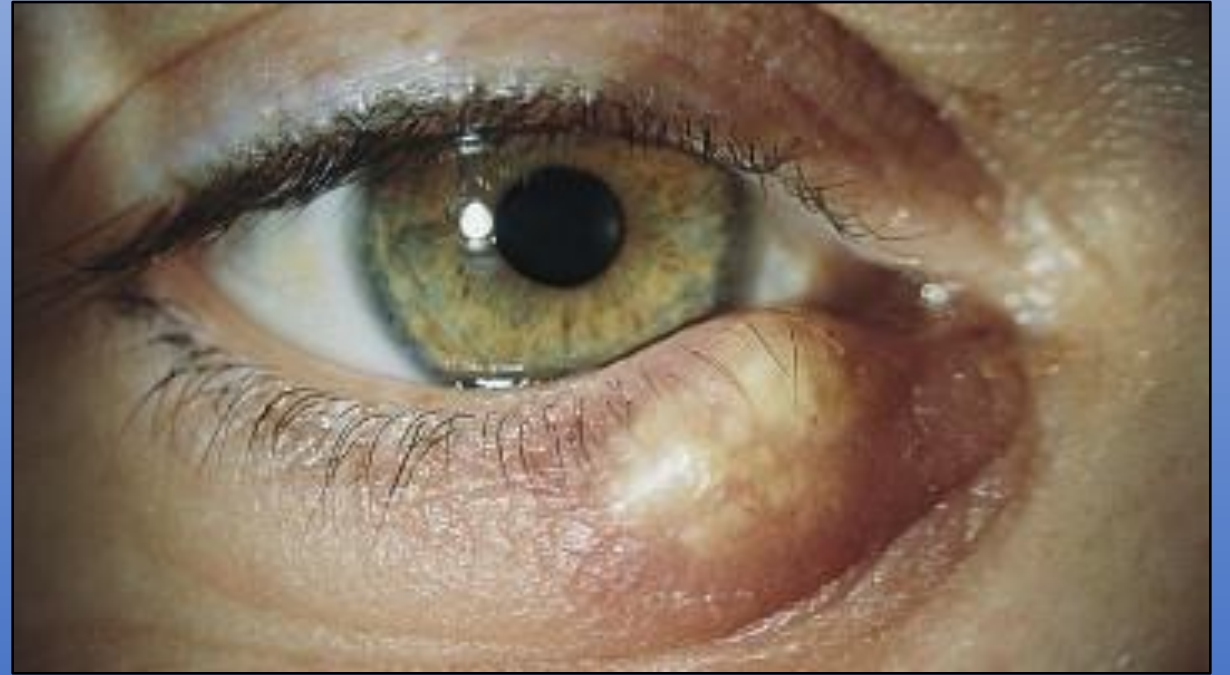
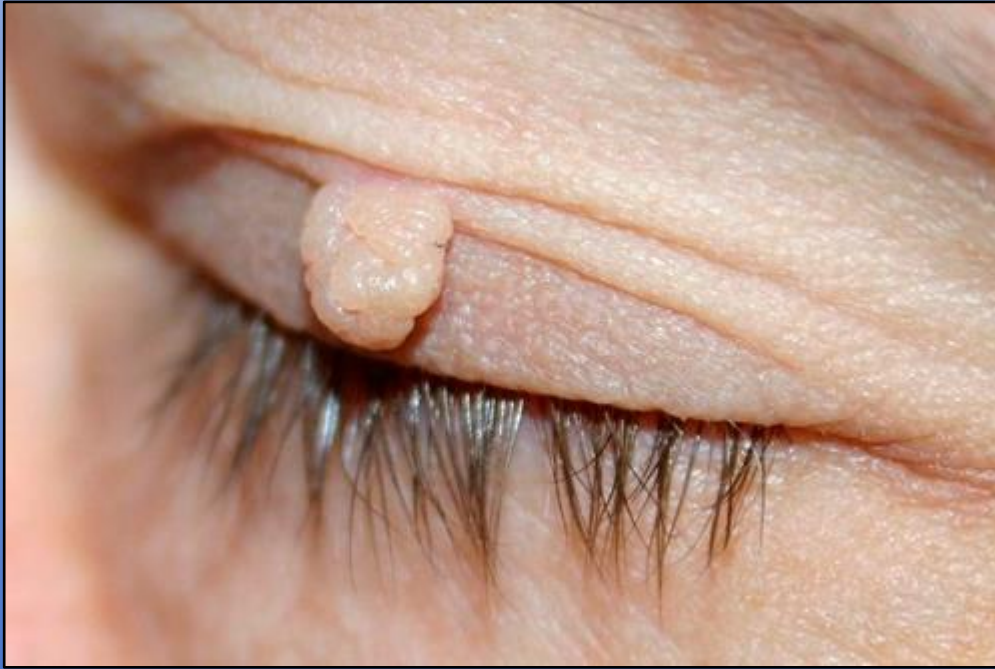


Surgical Management of Lumps and Bumps

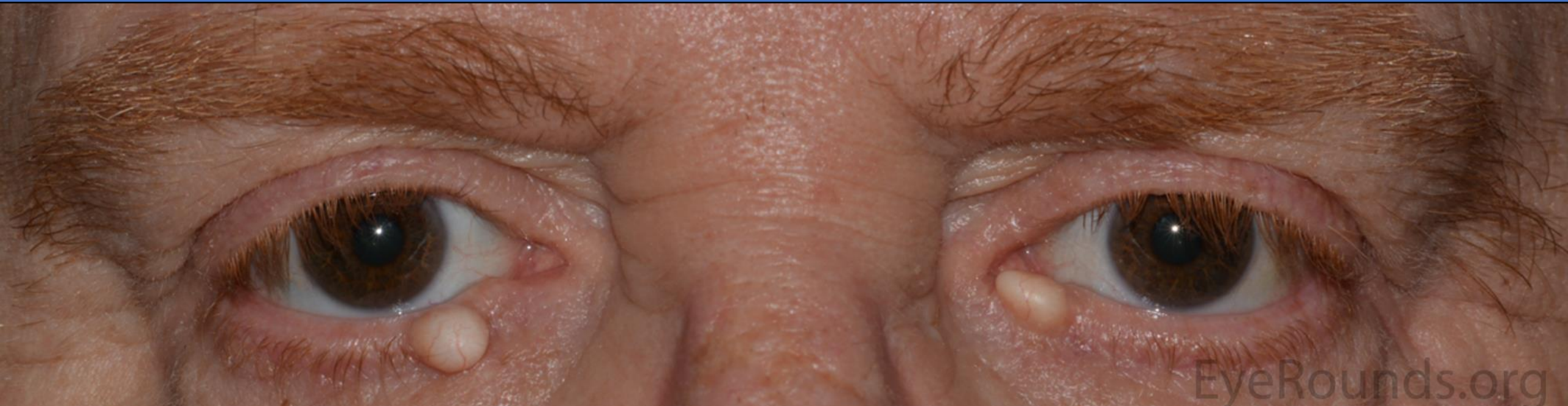Richard Trevino, OD
Indiana University School of Optometry

Minor Surgical Procedures

Email: rctrevin@iu.edu

Web: richardtrevino.net

Disclosures: No relevant
financial relationships to
disclose



Course Outline

1. General Considerations

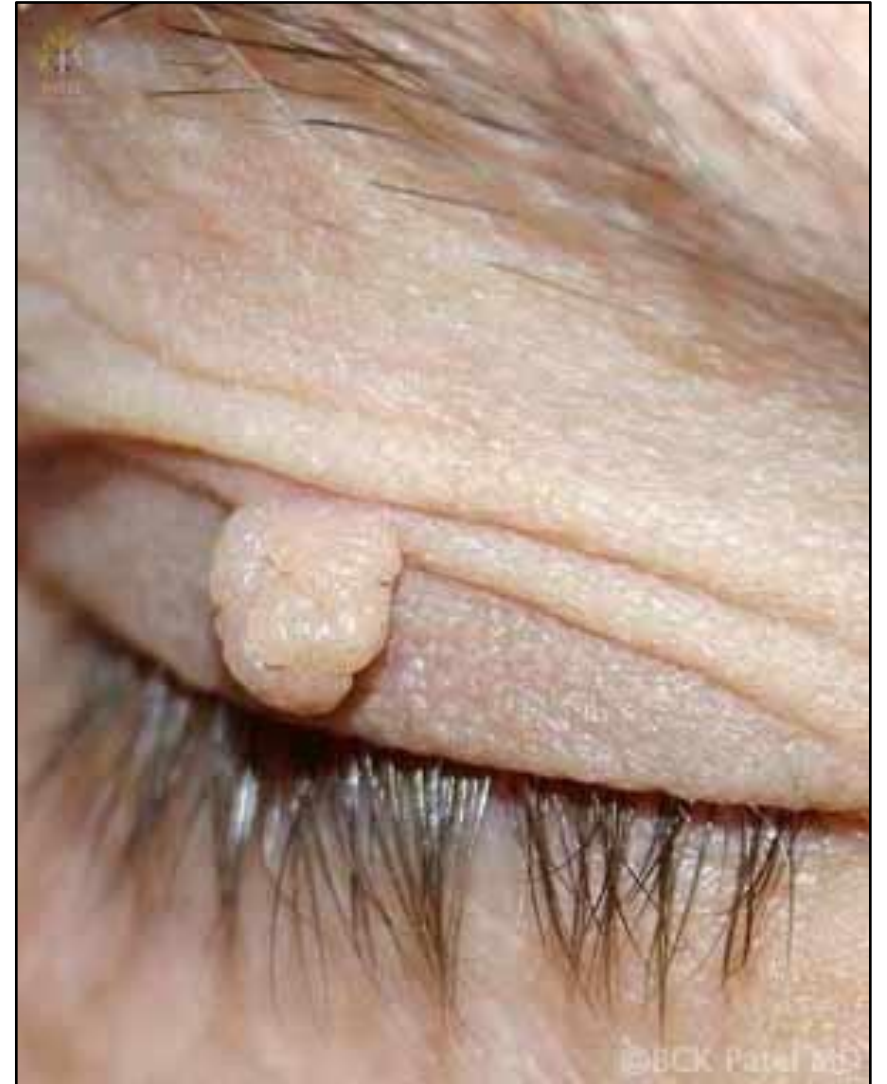
- Informed consent
- Documentation
- Local Anesthesia

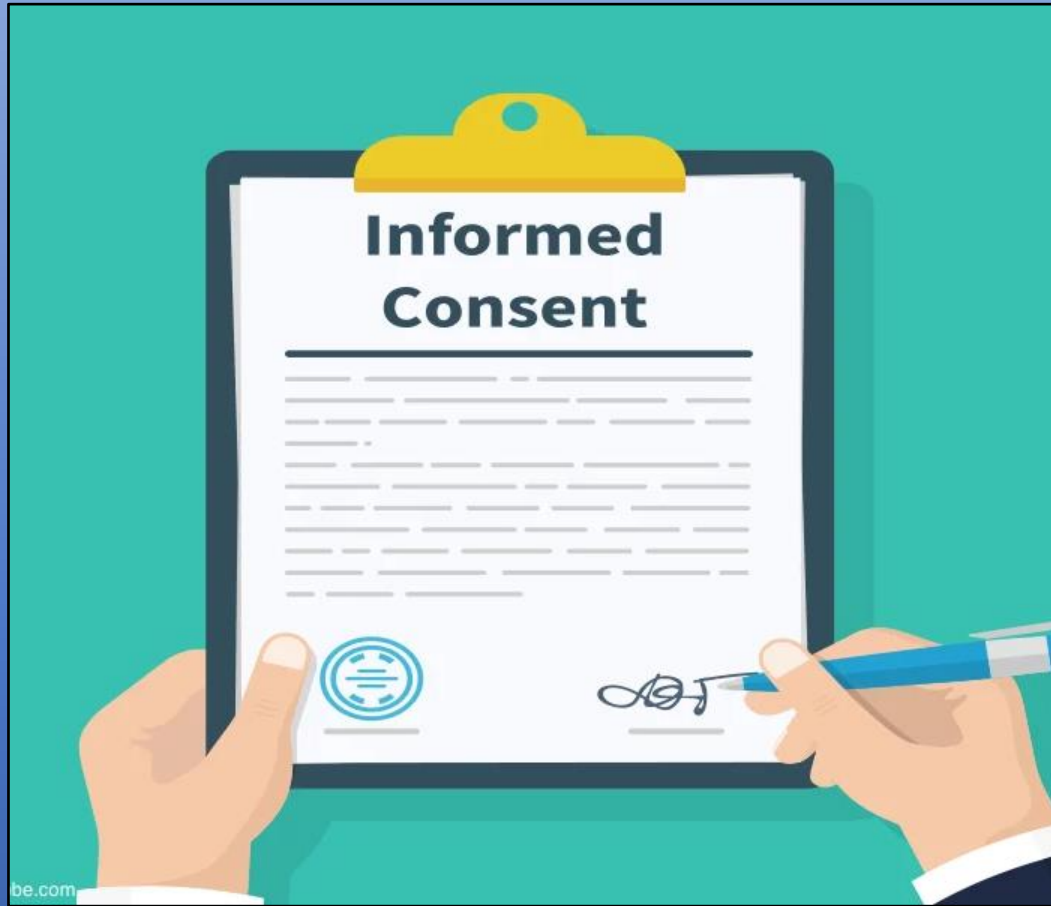
2. Excision of benign eyelid lesions

- Differentiating benign vs malignant lesions
- Excision techniques

3. Chalazion management

- Conservative
- Intralesional steroid injection
- Incision and curetteage





Informed Consent

Informed Consent

Three Fundamental Criteria

- 1. The patient must be competent** to make a voluntary decision about whether to undergo the procedure or intervention
- 2. The patient must be adequately informed**
 - Risks, benefits and alternatives
- 3. The consent must be voluntary**
 - Physicians are expected to **make recommendations** on a given course of action, but the final decision on how to proceed lies with the patient

Medical Battery

Battery consists of unpermitted, unprivileged, intentional contact with another person's body. The contact need not result in bodily harm; the contact itself is the harm.

Battery within a medical context may include the following:

1. Treatment with no consent at all, actual or implied
2. Treatment substantially different from that to which the patient consented
3. Performance of a consented-to procedure by a physician other than the one to whom consent was given

Battery is not covered under medical malpractice insurance

Sample consent form Chalazion I&C



Minor Surgical Procedure Consent Form

Patient Name

Date

1. I understand the following condition requires further treatment: _____
2. I understand the following has been proposed as a treatment: **Incision and curettage**
3. The procedure will be performed by Dr. _____
4. I have been informed of the expected benefits of this procedure, as well as possible alternatives, including the risk of no treatment.
5. I understand all therapeutic procedures involve risks to some degree. These risks may include:
 - a. Scarring may be a possible result
 - b. Discomfort: possible allergic reaction at the injection site, minor post-operative pain
 - c. Possible need for referral for subsequent surgery
6. I consent to observers in the treatment room for the purpose of advancing optometric education.
7. I fully understand the contents of this form. I have had sufficient opportunity to discuss my condition and the proposed procedure with my doctor, and all my questions have been answered regarding the nature of the procedure, alternative options, and risks or complications.
8. The choice to undergo this procedure is mine, and I hereby give my consent.

Patient Signature

Date **Time** **am** **pm**

Witness Signature

Date **Time** **am** **pm**

If patient is unable to give consent:

Signature of person authorized to consent for patient

Printed name of person signing

Relationship to patient: _____

Procedure Note – Skin tag removal using RF

Risks/Benefits/Alternative procedures/Potential complications explained to patient. Consent was reviewed and signed. All questions were answered. Area was prepped with alcohol swab and Betadine. Approximately 0.4cc lidocaine 1% with epi was injected around area to provide anesthesia. Lesion was excised down to the level of the orbicularis with RF unit bent tip electrode. No sutures were required. Erythro ung applied to area. Pt to use 3x/day until tube runs out. Pt tolerated the procedure well and left in NAD.

Procedure Note – Skin tag removal using RF

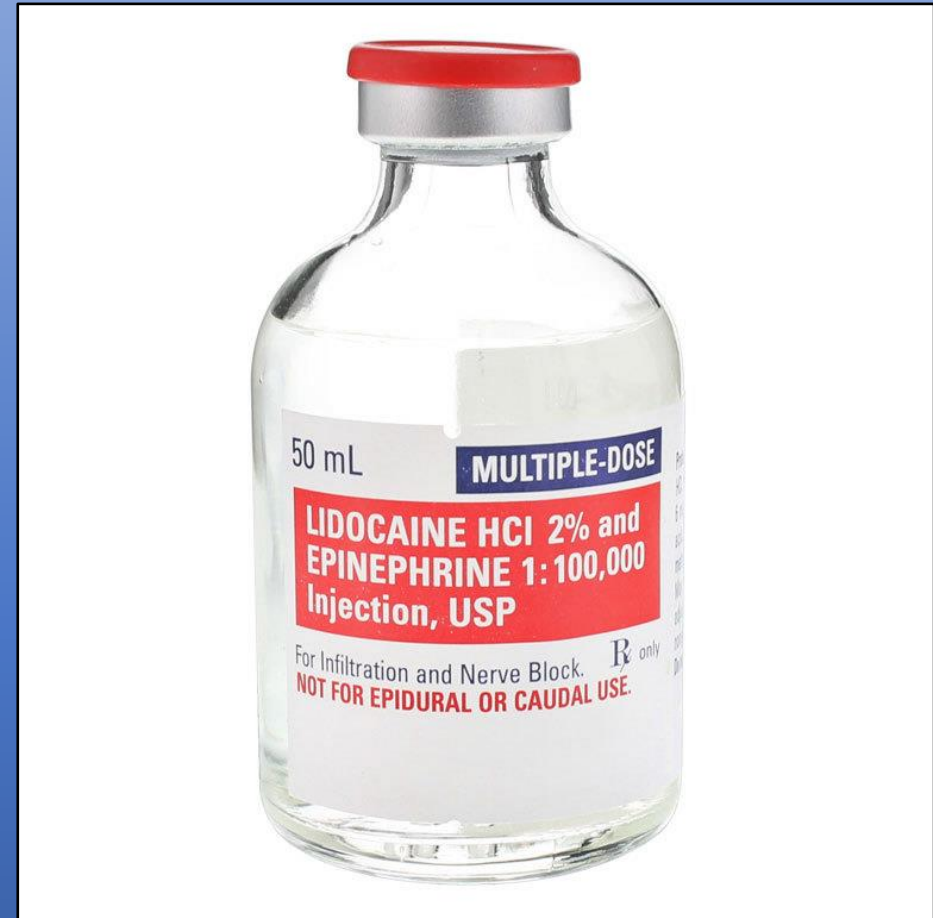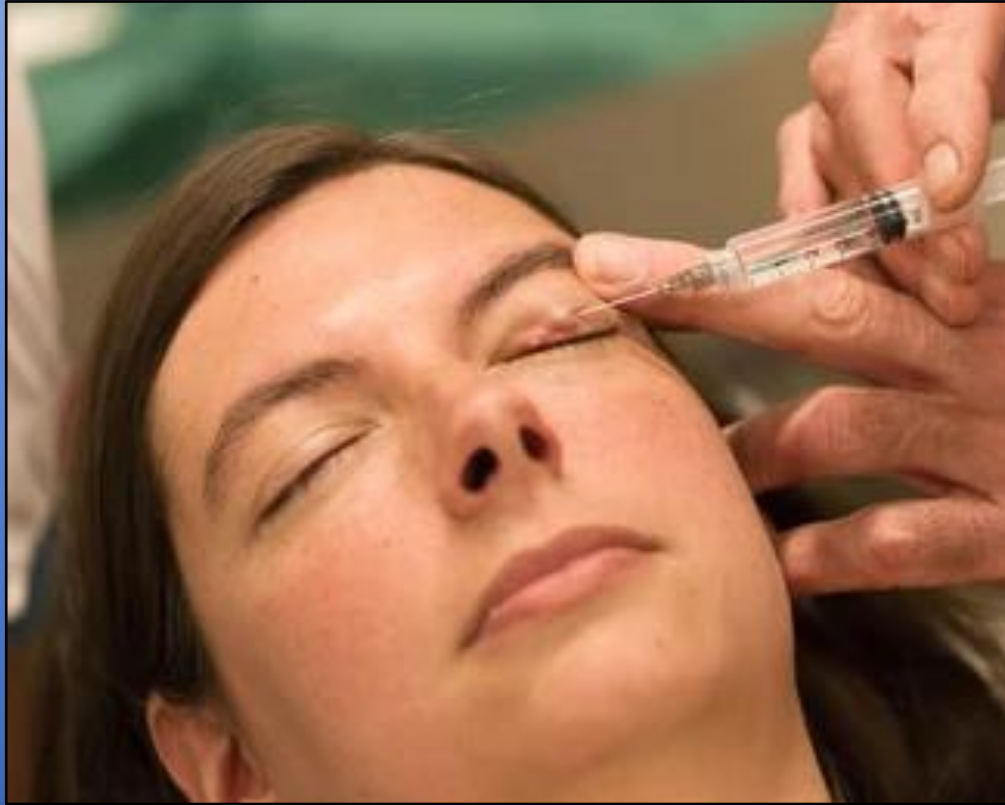Risks/Benefits/Alternative procedures/Potential complications explained to patient. Consent was reviewed and signed. All questions were answered. Area was prepped with alcohol swab and Betadine. Approximately 0.4cc lidocaine 1% with epi was injected around area to provide anesthesia. Lesion was excised down to the level of the orbicularis with RF unit bent tip electrode. No sutures were required. Erythro ung applied to area. Pt to use 3x/day until tube runs out. Pt tolerated the procedure well and left in NAD.

Procedure Note – Skin tag removal using RF

Risks/Benefits/Alternative procedures/Potential complications explained to patient. Consent was reviewed and signed. All questions were answered. Area was prepped with alcohol swab and Betadine. Approximately 0.4cc lidocaine 1% with epi was injected around area to provide anesthesia. Lesion was excised down to the level of the orbicularis with RF unit bent tip electrode. No sutures were required. Erythro ung applied to area. Pt to use 3x/day until tube runs out. Pt tolerated the procedure well and left in NAD.

Procedure Note – Skin tag removal using RF

Risks/Benefits/Alternative procedures/Potential complications explained to patient. Consent was reviewed and signed. All questions were answered. Area was prepped with alcohol swab and Betadine. Approximately 0.4cc lidocaine 1% with epi was injected around area to provide anesthesia. Lesion was excised down to the level of the orbicularis with RF unit bent tip electrode. No sutures were required. Erythro ung applied to area. Pt to use 3x/day until tube runs out. Pt tolerated the procedure well and left in NAD.



Fundamentals of Local Anesthesia

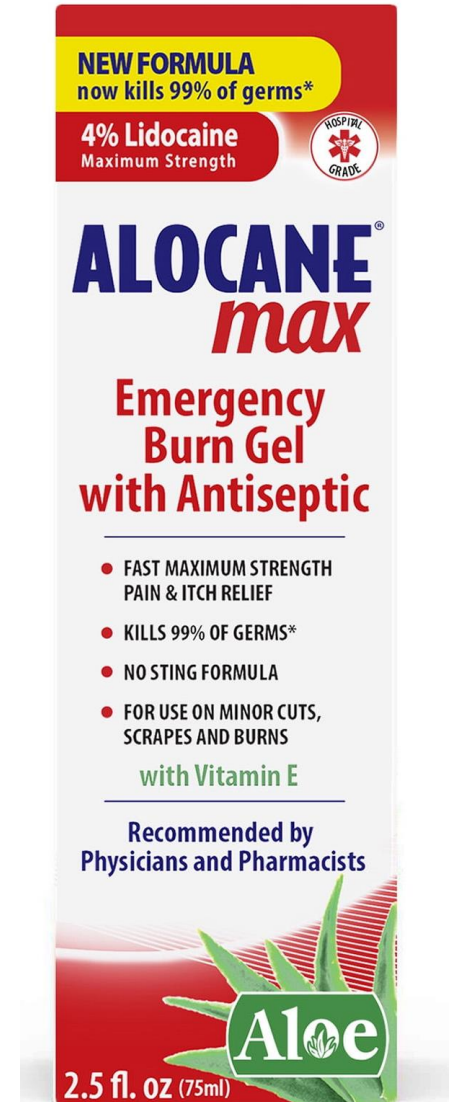
Topical Anesthesia

Proparacaine

- **Almost universally applied prior to any procedure** involving the lids
- Decreases blink reflex
- Avoids discomfort associated with use of antiseptic agents (povidone iodine) that are used prior to surgery

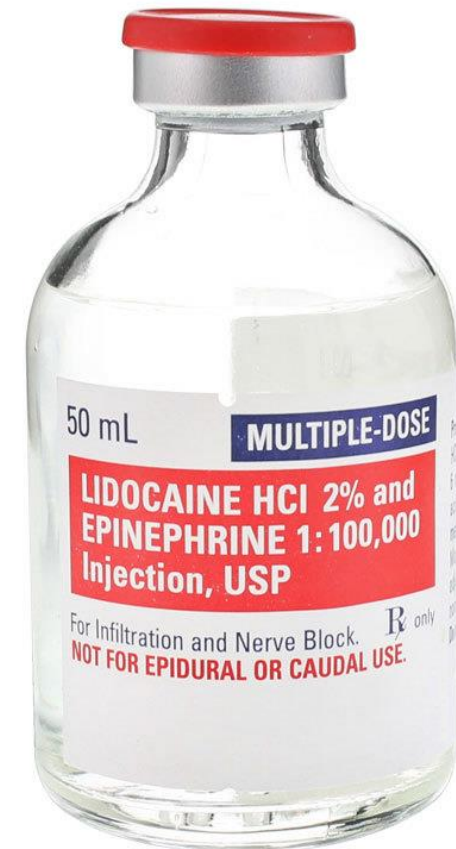Lidocaine Gel

- **Enables deeper anesthesia to a localized area**
- Gel is administered on a cotton-tipped applicator that is held on the site
- May be used prior to chalazion injection or procedures on the lid margin



Local cutaneous infiltration anesthesia

- Direct injection of anesthetic into the area requiring anesthesia
- **Lidocaine (with or without epinephrine)** is the most frequently used agent
- Epinephrine prolongs duration of anesthesia, decreases bleeding and reduces systemic absorption
- Lidocaine is packaged as a weak acid
 - **Add sodium bicarbonate immediately before use** to neutralize pH and minimize the discomfort caused by injecting an acidic solution



Contraindications for Lidocaine

Allergy

- Allergy to lidocaine is rare, but allergy to preservative is fairly common (methylparaben)

Liver failure

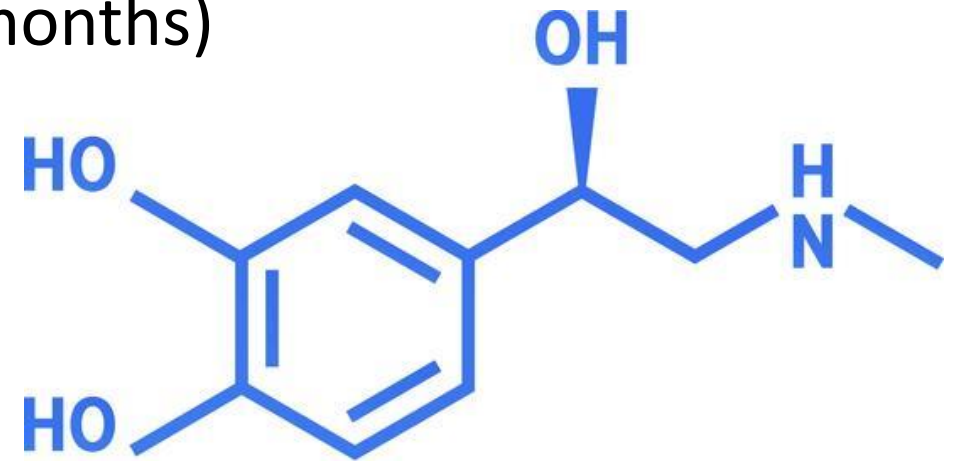
- Lidocaine is metabolized by the liver

H/O adverse reaction to local anesthetics

- Some patients are very sensitive to local anesthetics
- **Ask if they have ever had an adverse reaction to anesthesia during dental procedures**
 - CNS (Circumoral numbness, tinnitus), Cardiovascular (hypotension), Cardiopulmonary (apnea)

Contraindications for Epinephrine

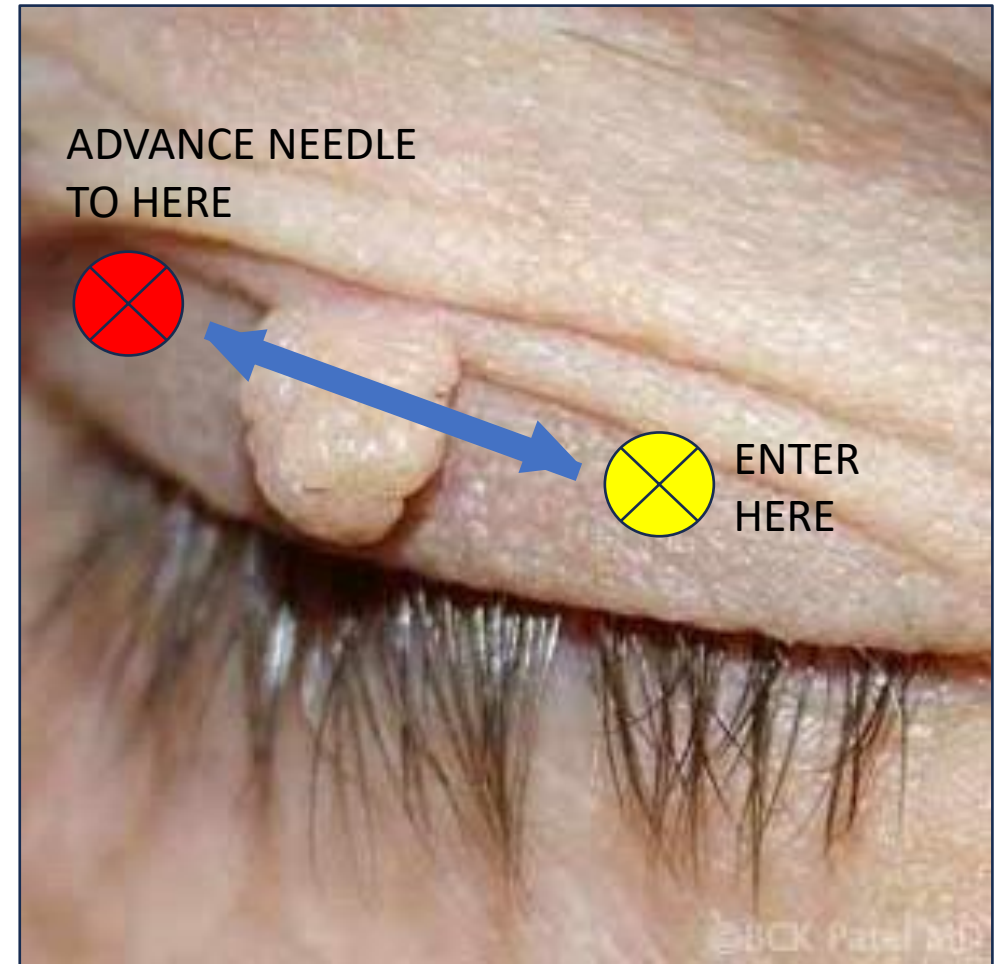
- **Recent heart attack or stroke** (within 6 months)
- **Uncontrolled** or severe hypertension
- **Uncontrolled** diabetes
- **Uncontrolled** hyperthyroidism
- Peripheral vascular disease (poor circulation in legs)
- Sulfite sensitivity (asthma-like reactions to certain food preservatives)

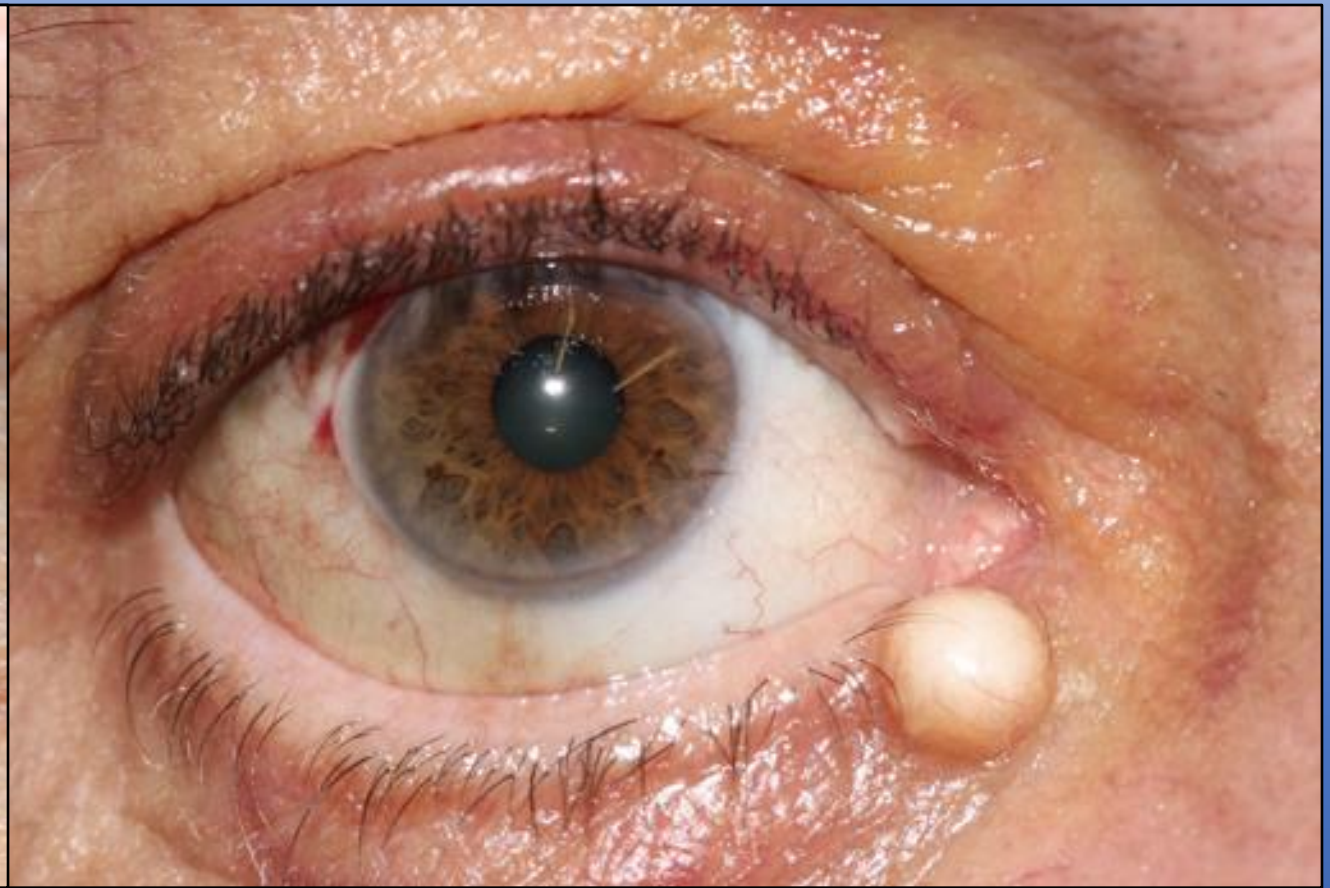
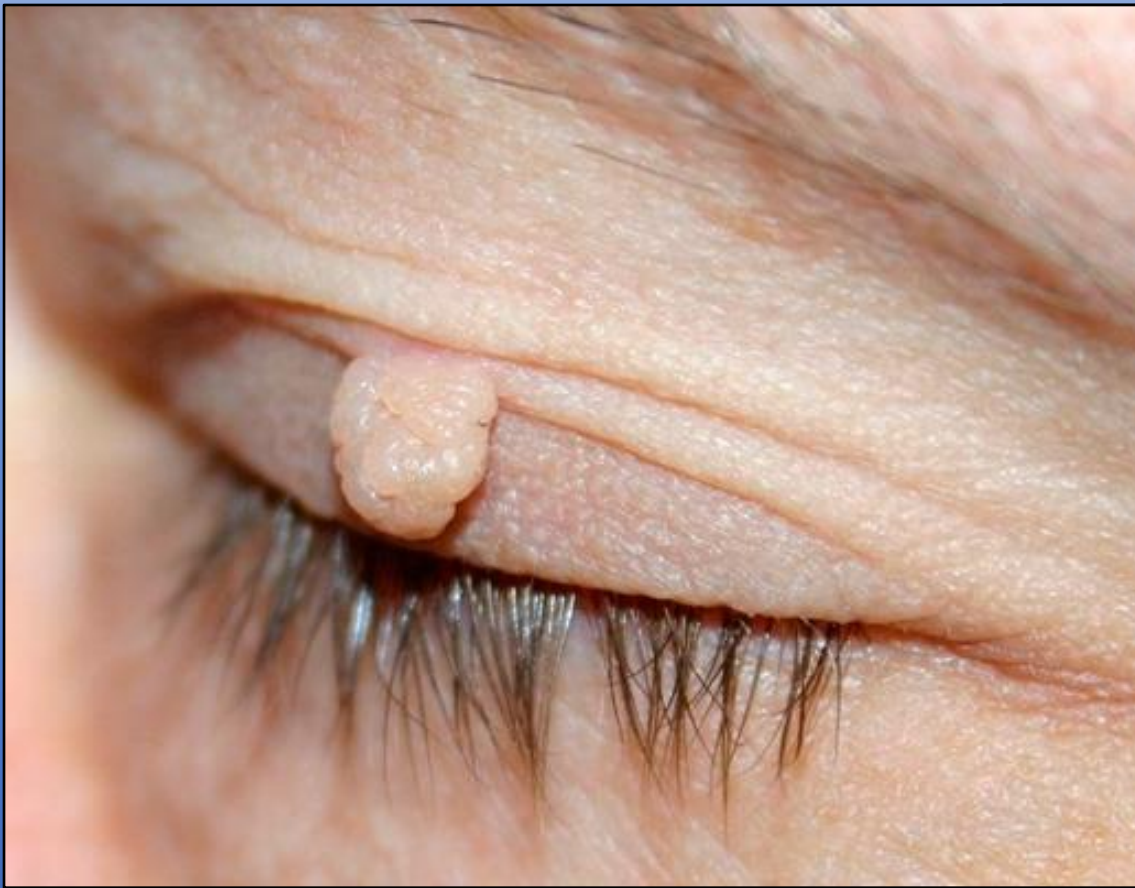

**ADRENALIN
(EPINEPHRINE)**

Eyelid Injection Procedure

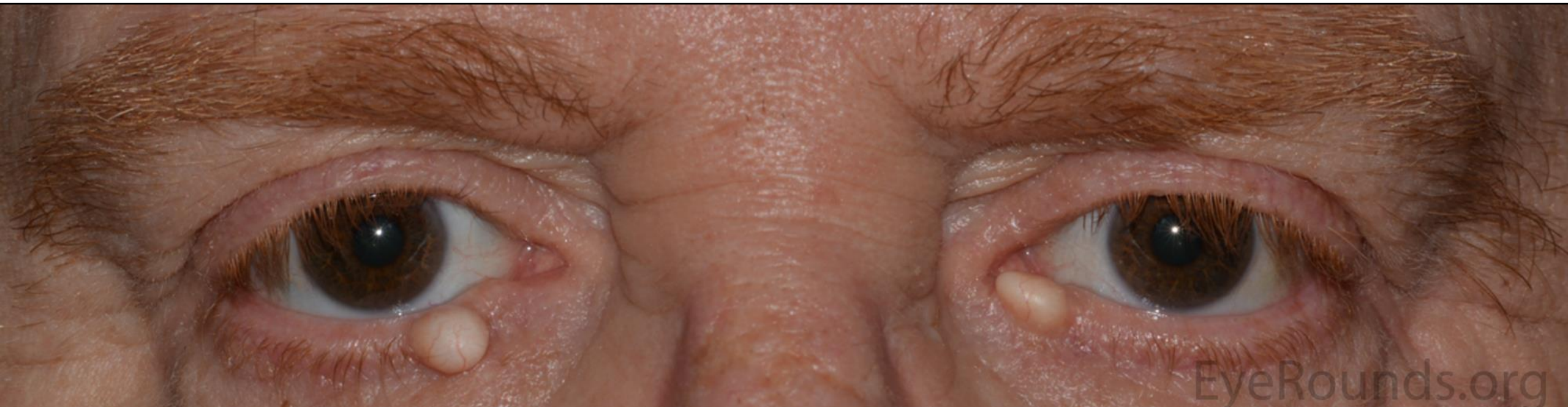- Use small gauge needle (TB syringe)
- **Stay just below the surface of the skin.** Aim the tip of the needle away from the globe
- **Slowly inject the anesthetic as you withdraw the needle**
- Onset of anesthesia in about 5 min. Test anesthesia by pinching with forceps. Duration is 2 hrs w/o epi and 3 hrs with epi





Excision of Benign Eyelid Lesions

1. Classify lesion as benign or malignant
2. Identify contraindications
3. Informed consent
4. Photodocument the lesion (before and after)
5. Administer anesthesia
6. Perform the excision
7. Send specimen to pathology
8. Post-procedure care



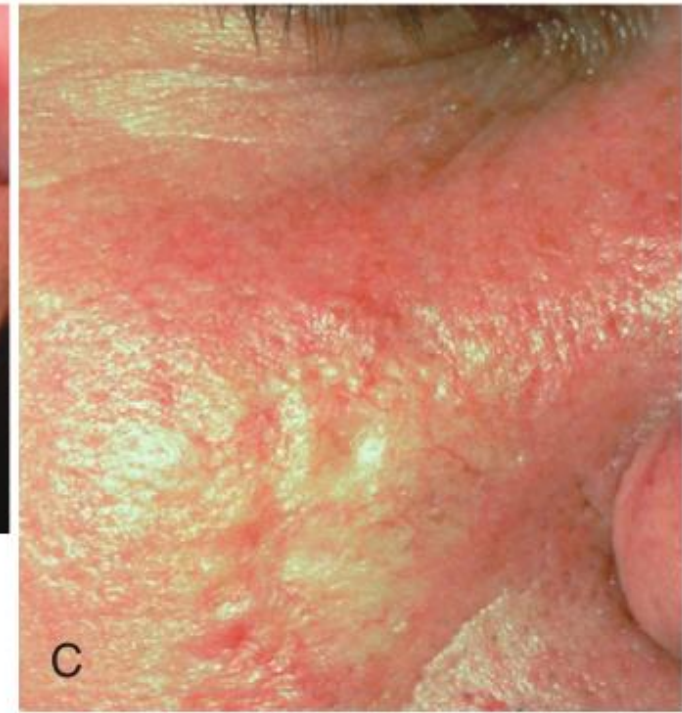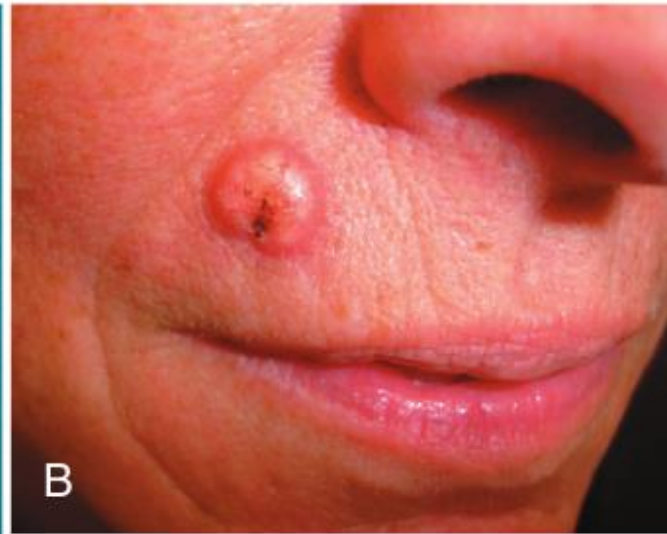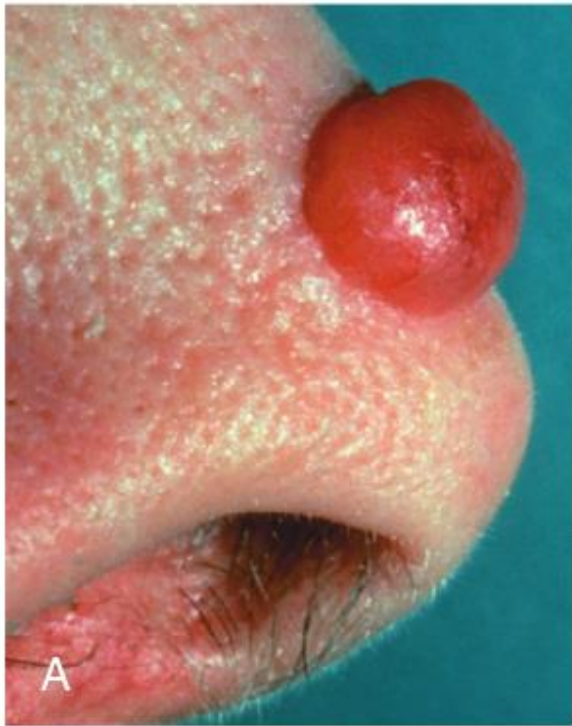Is the lesion benign or malignant?

Difficult to diagnose accurately based on history and appearance alone

- **All excised lesions should be sent to pathology for diagnosis**

Basic principles to identify eyelid lesions as benign or malignant

- Benign lesions
 - Commonly grow out from normal epithelium
 - Typically uniform, smooth, or papillary
- Malignant lesions
 - Create true anatomical/morphological destruction
 - Often involve bleeding, ulceration, and irregularity
- **A long-standing and stable lesion is more likely benign, while a recent-onset and rapidly growing lesion is potentially malignant**



Examples of
basal cell
carcinoma

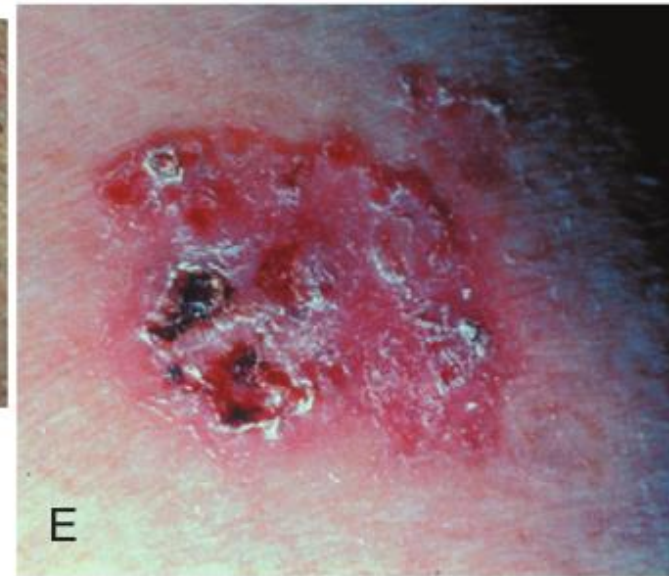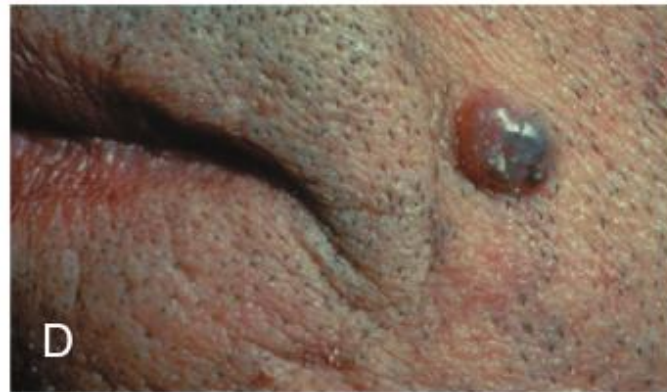
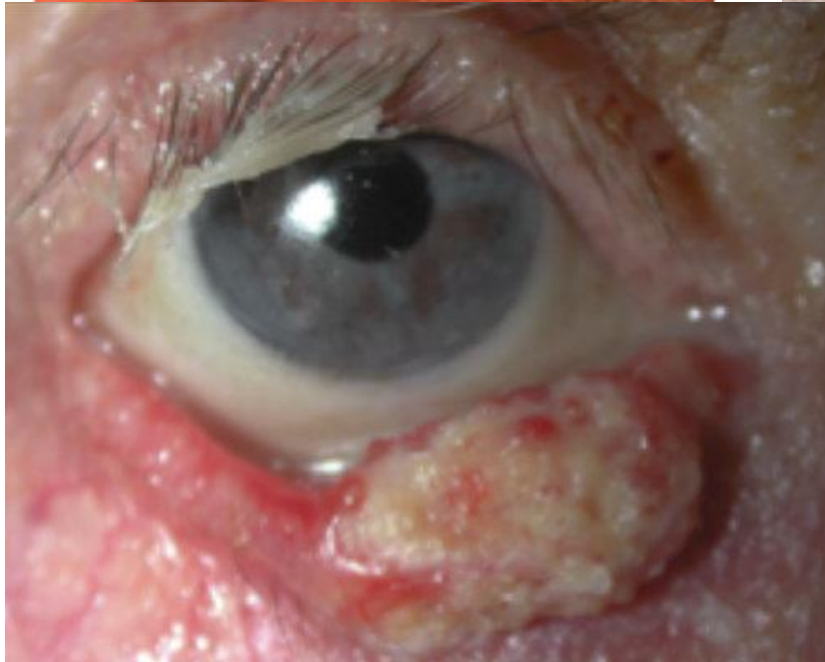

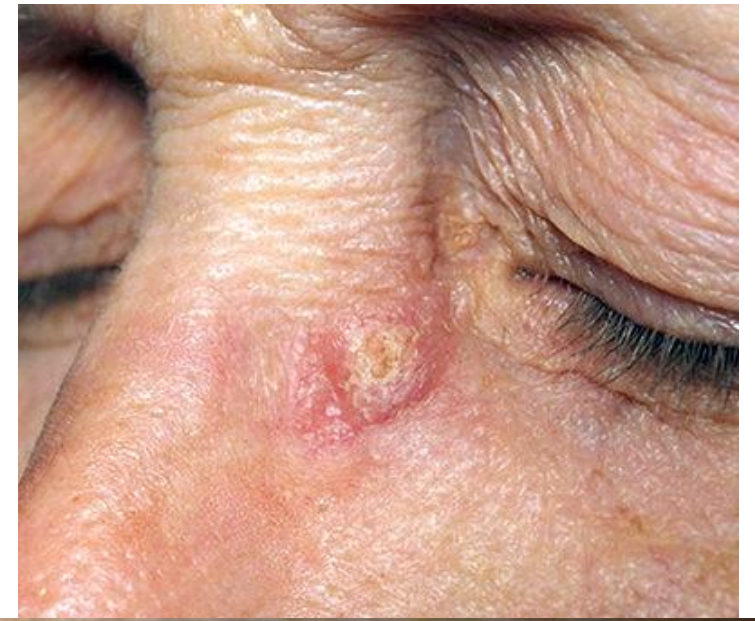
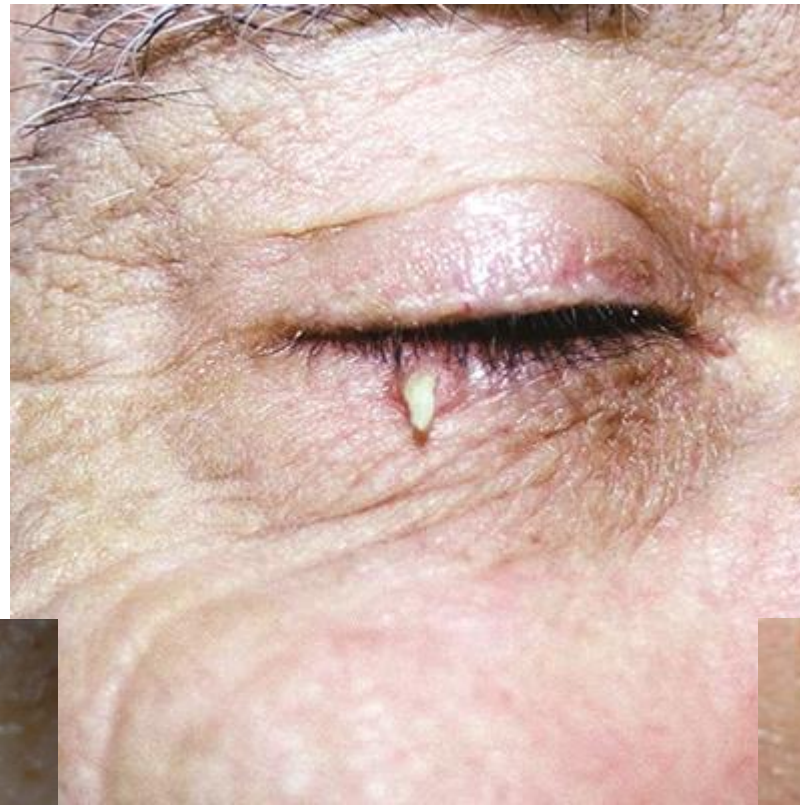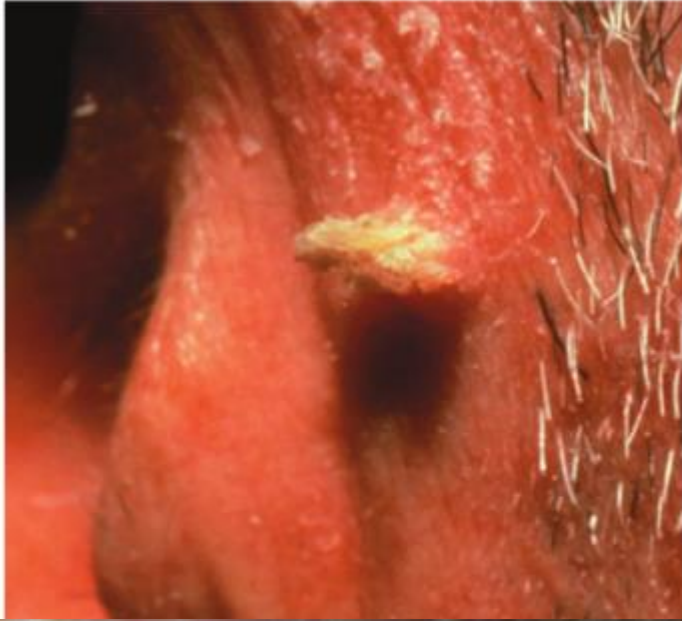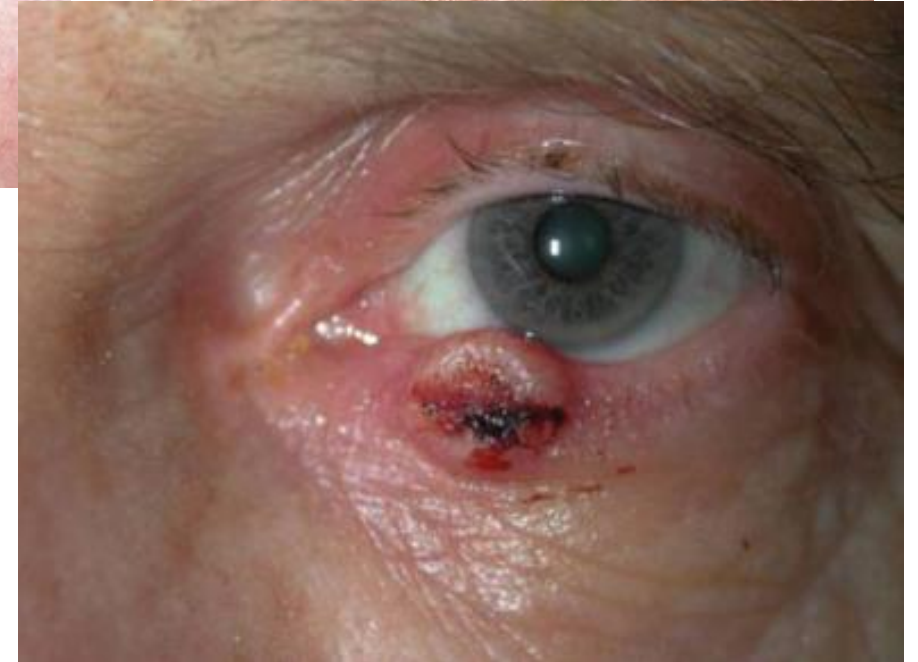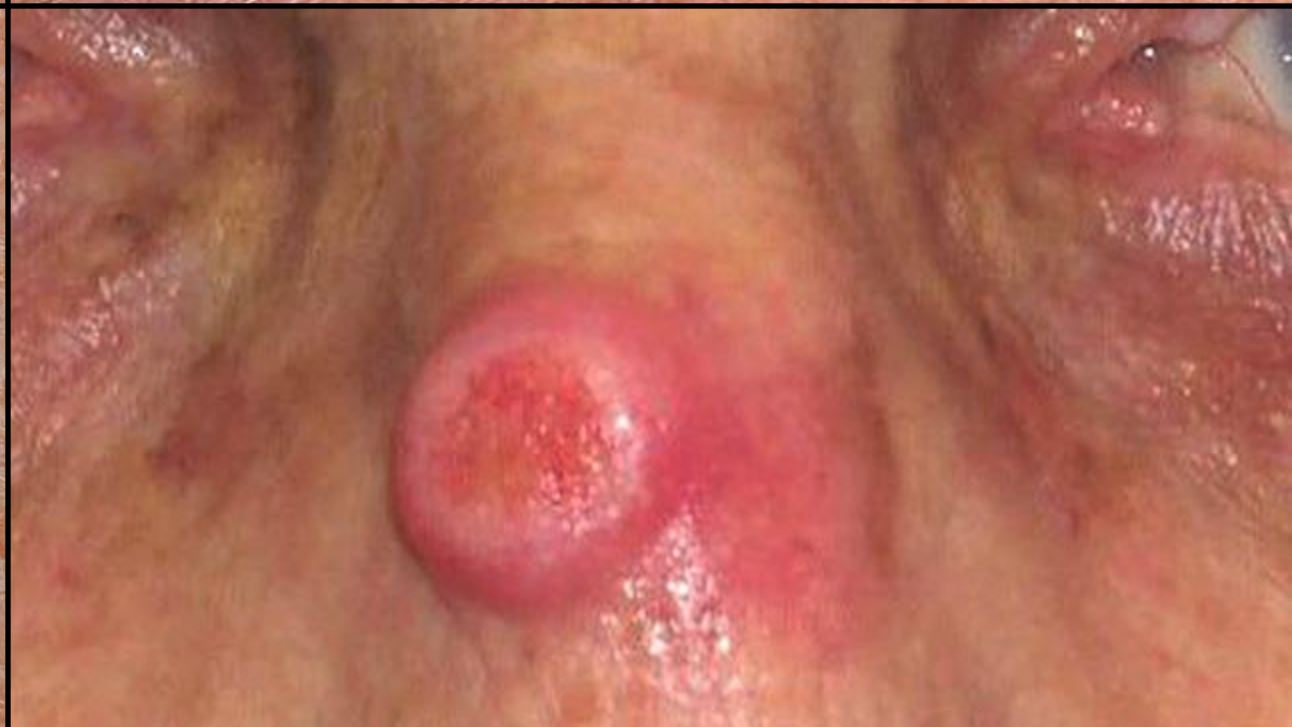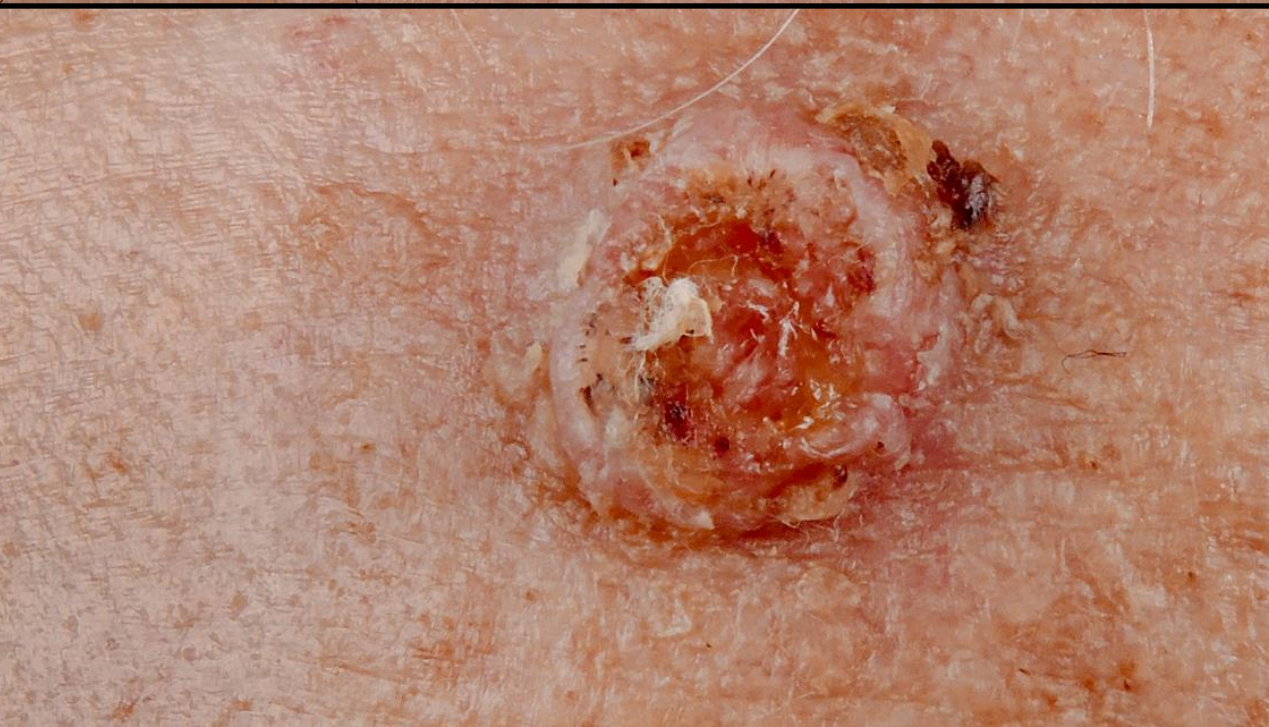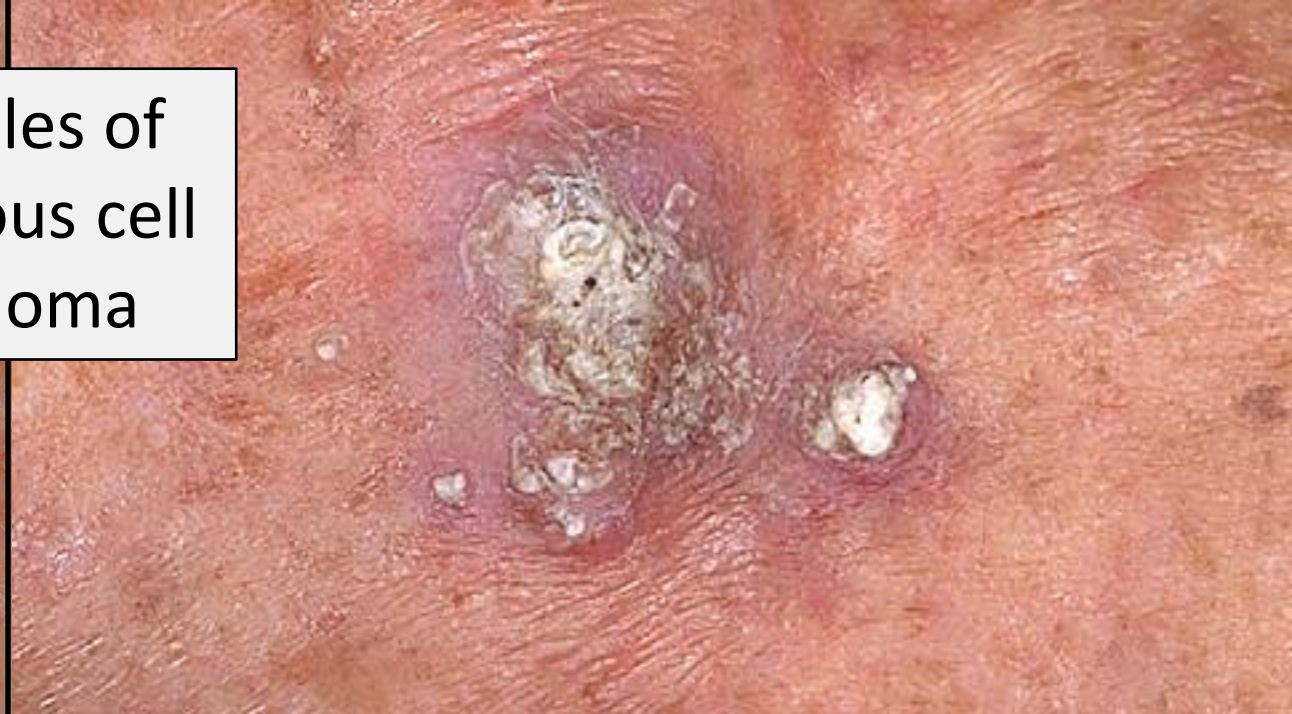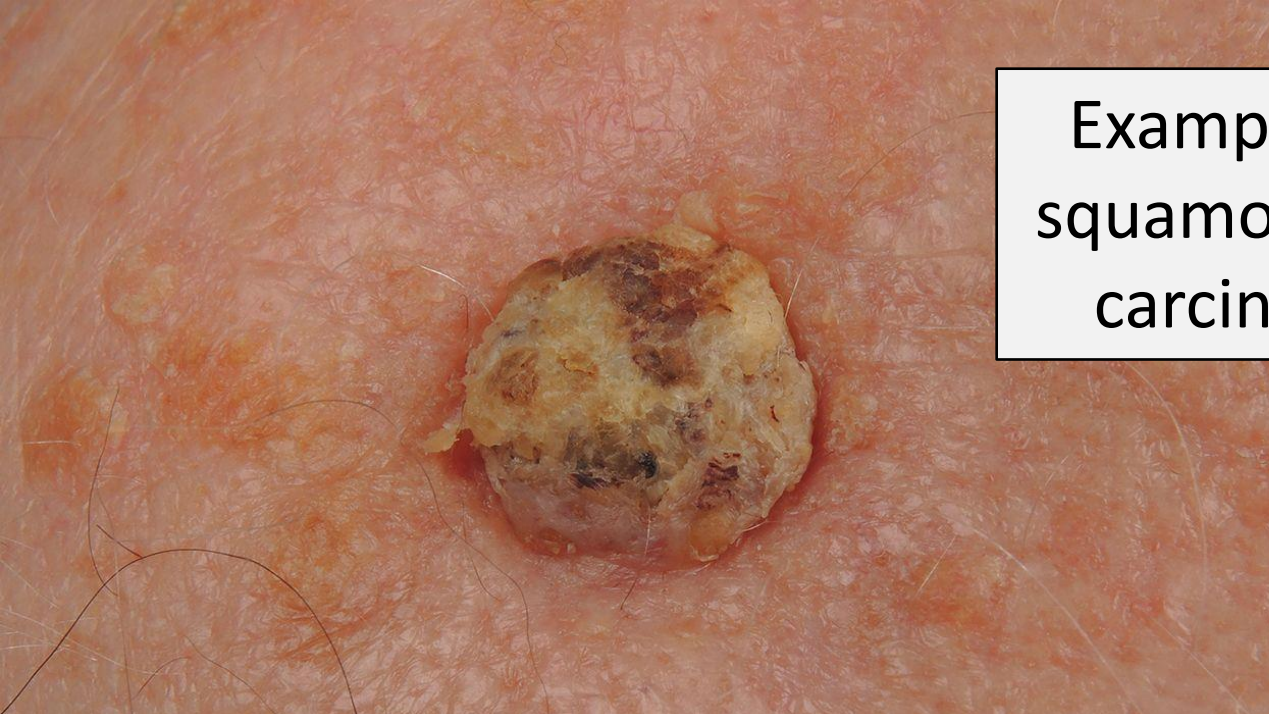Figure 12-5 Basal cell carcinoma. **A**, Nodular; **B**, nodular ulcerative; **C**, morpheaform; **D**, pigmented; **E**, superficial.

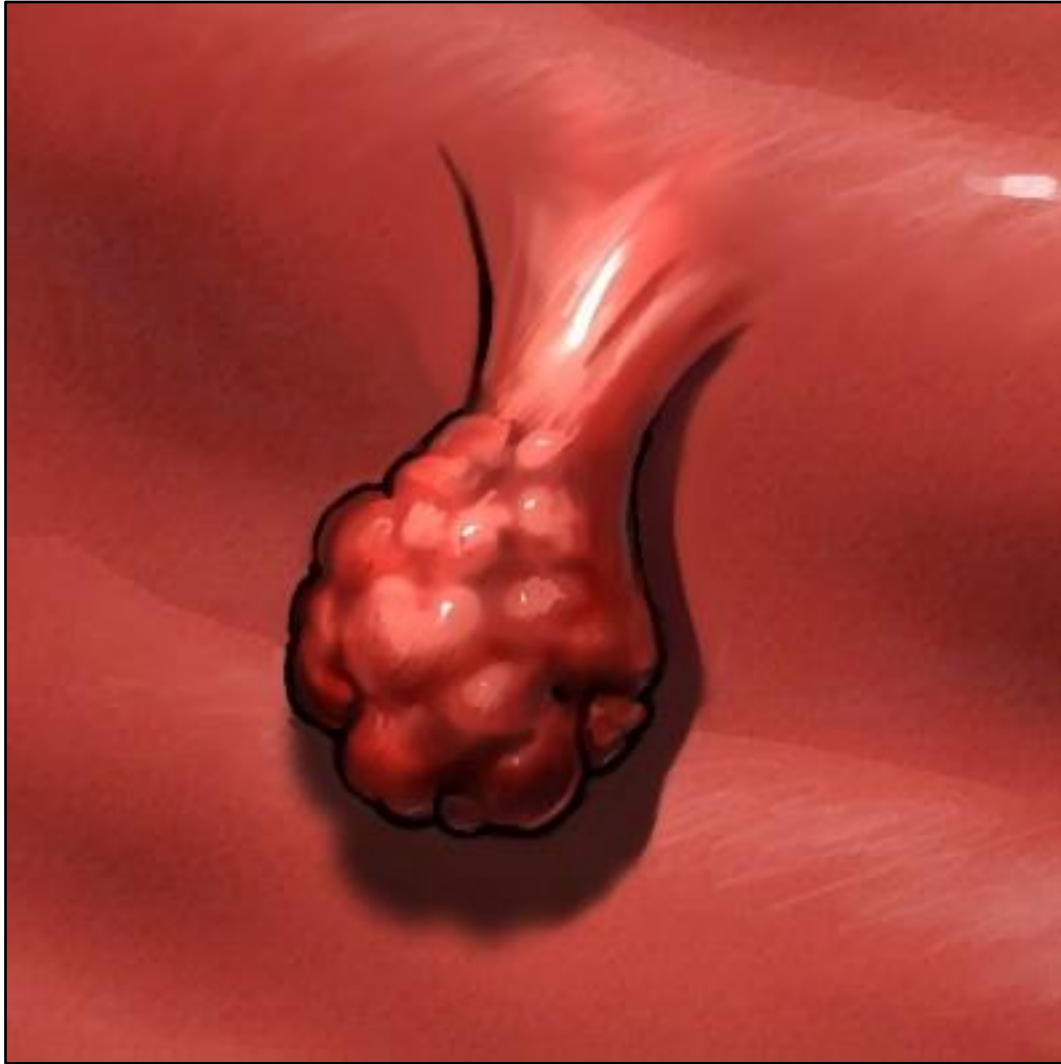

Examples of
squamous cell
carcinoma



Examples of squamous cell carcinoma





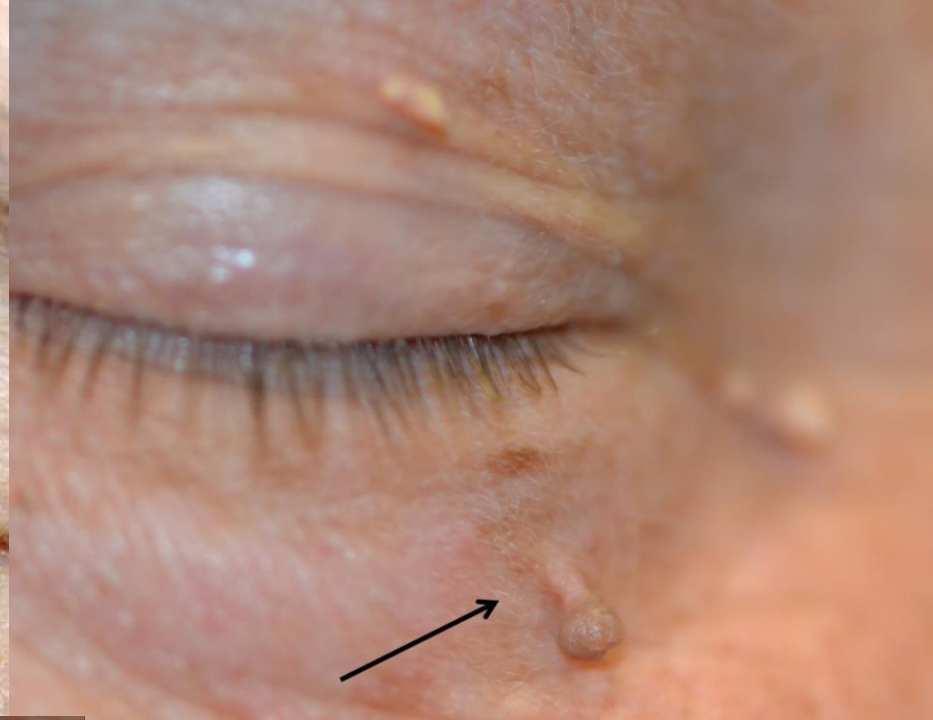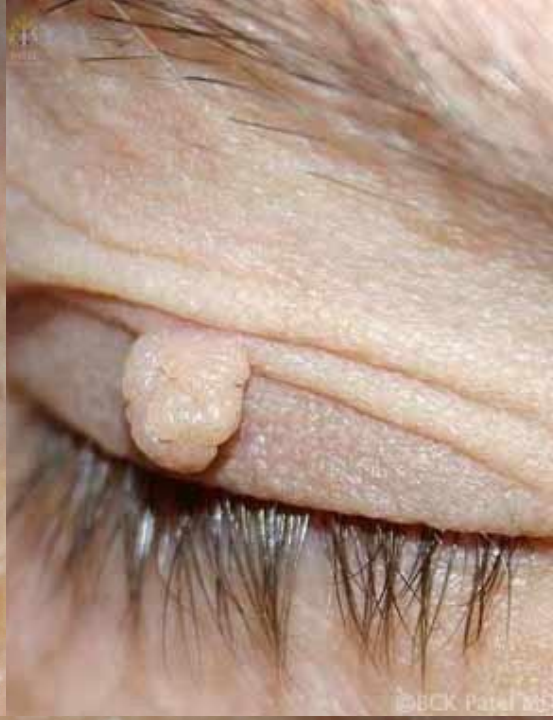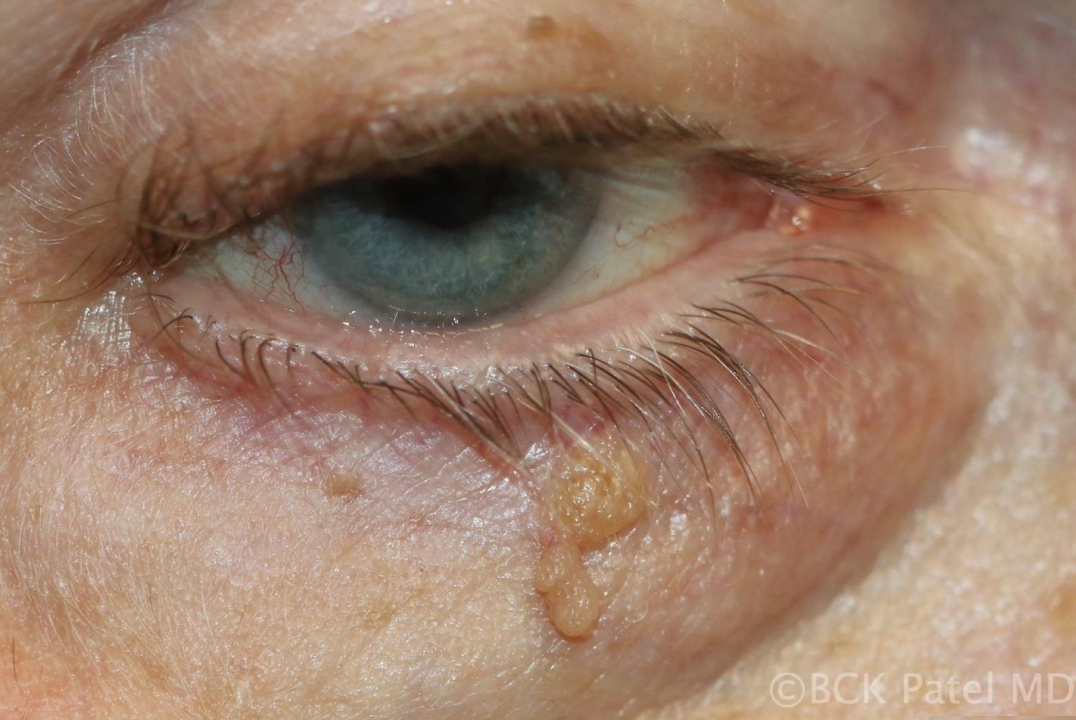
Common Benign Lesions

Acrochordon

- A-kroh-KOR-dun
- Descriptive of lesion morphology
- Any lesion attached by a stalk
- “Skin tag”

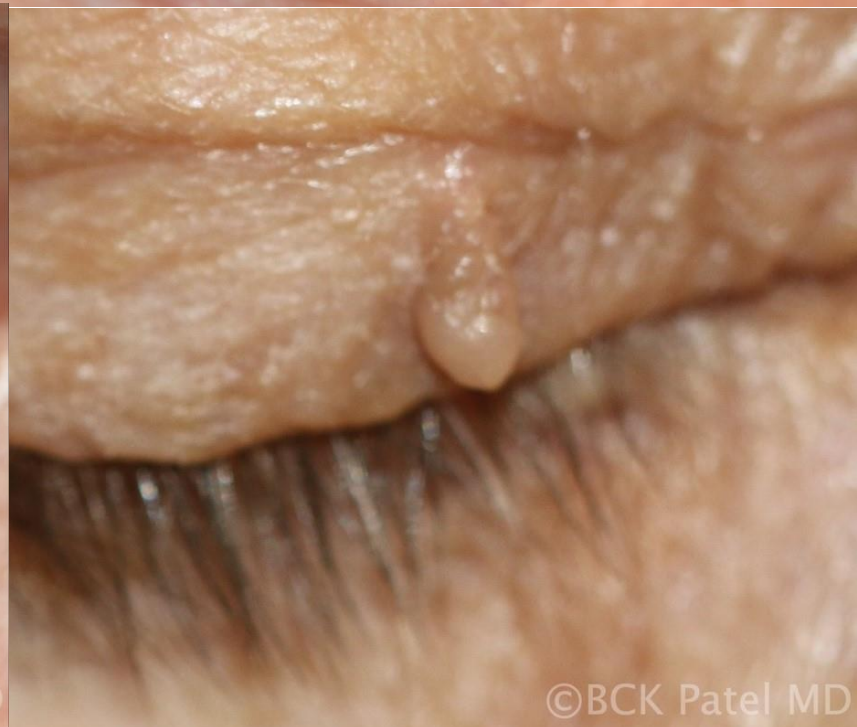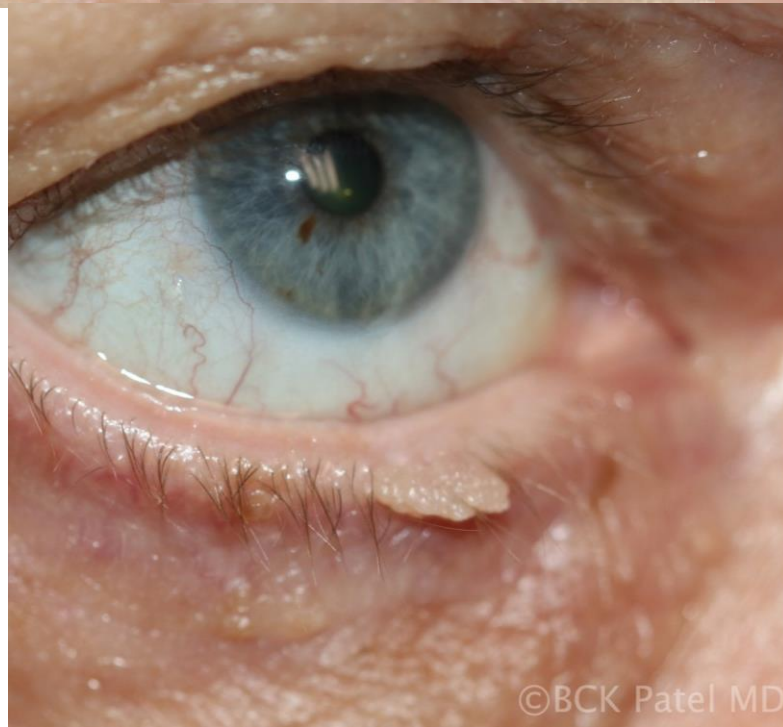Such lesions are *almost* universally benign

Excise at the base of the stalk and send to pathology for histologic confirmation



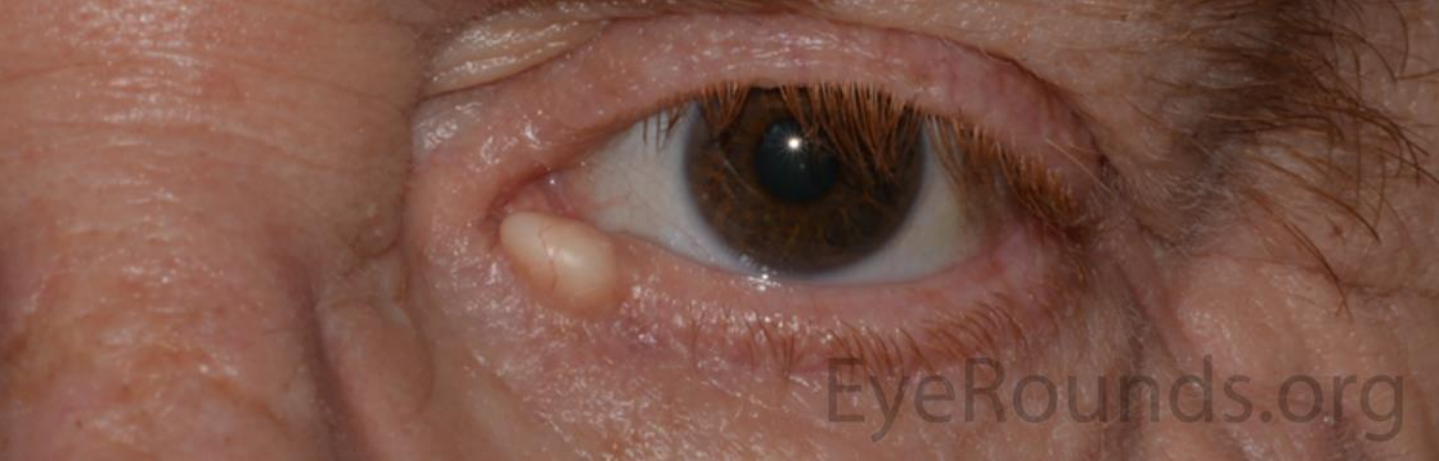
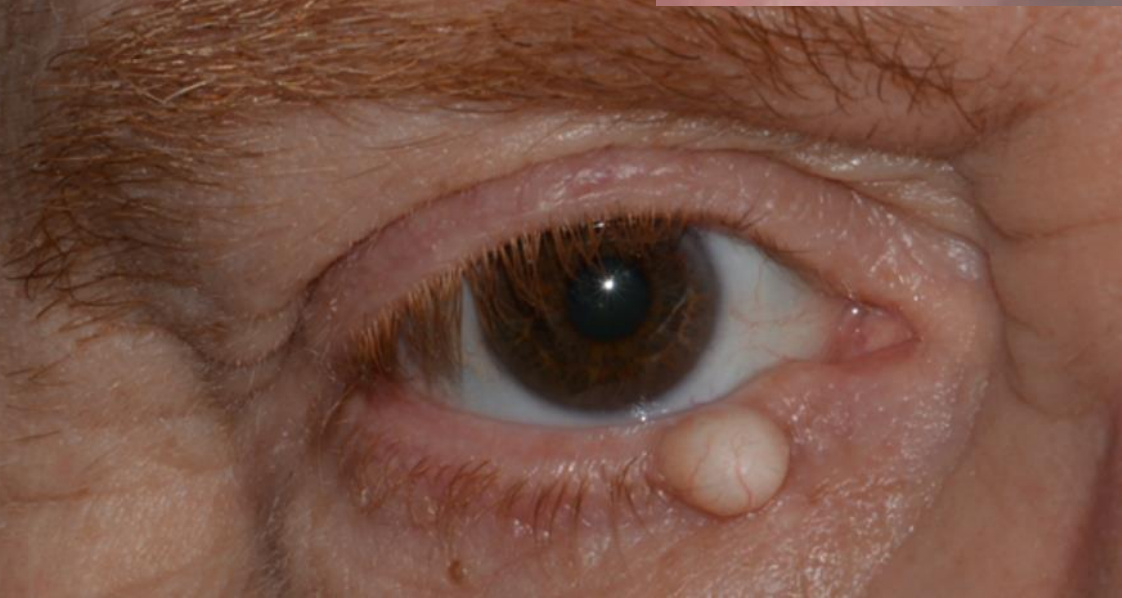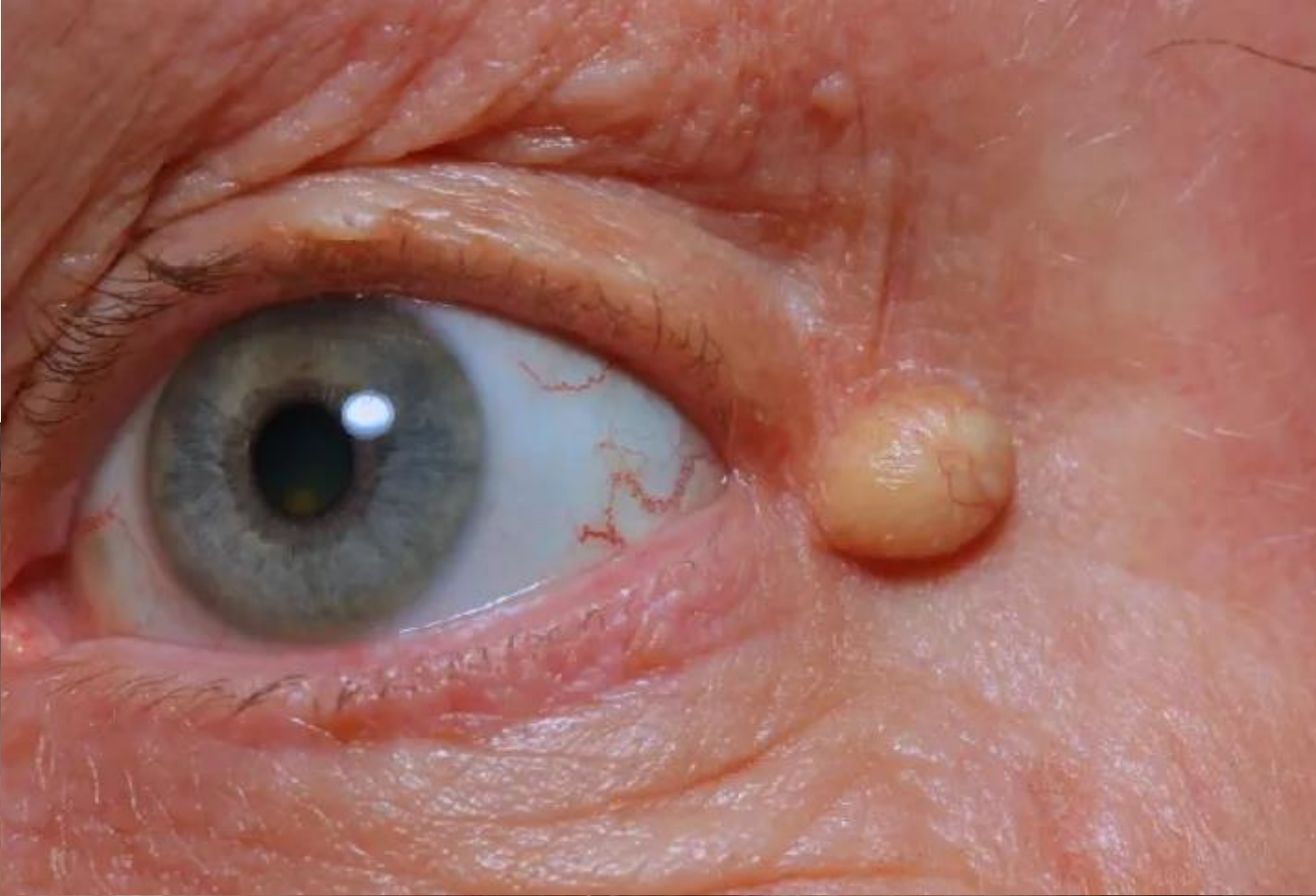
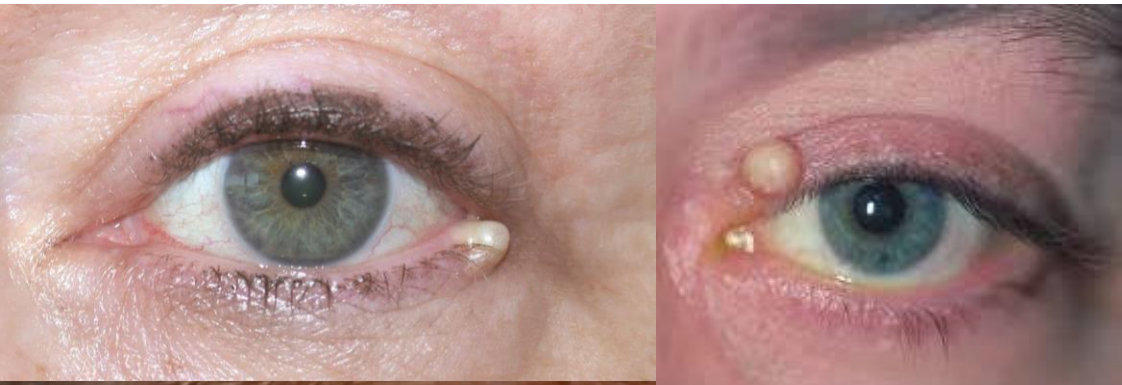Papillomas

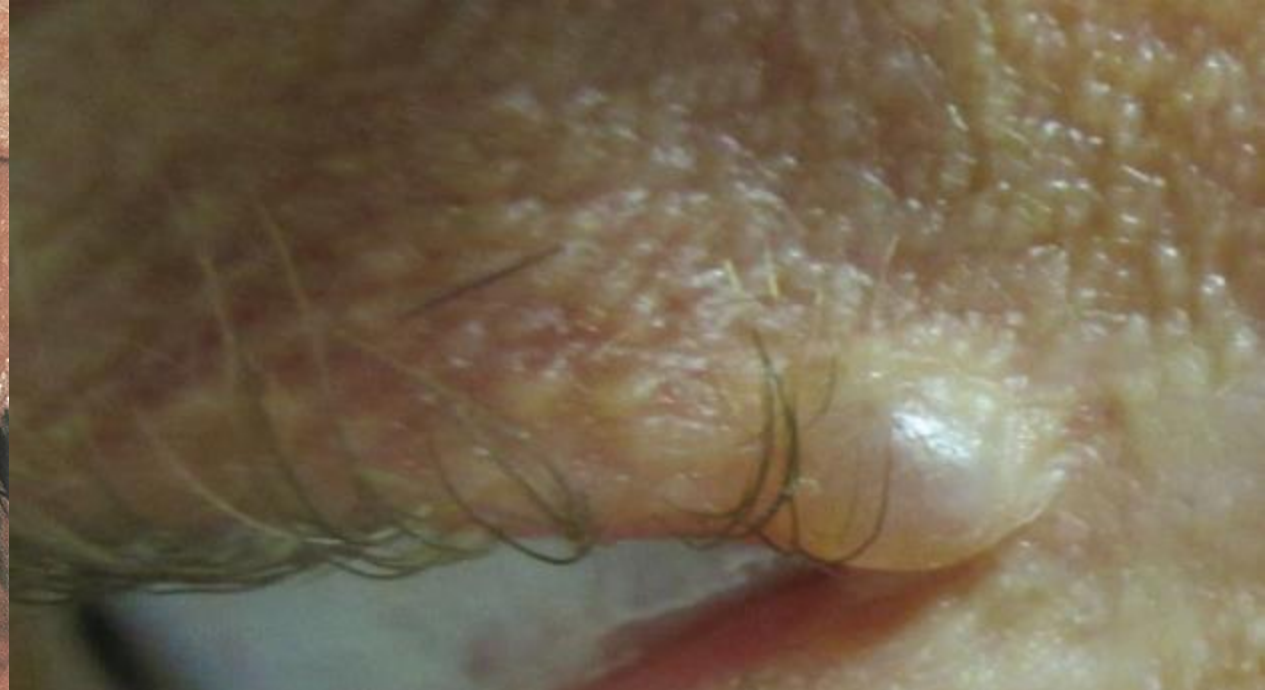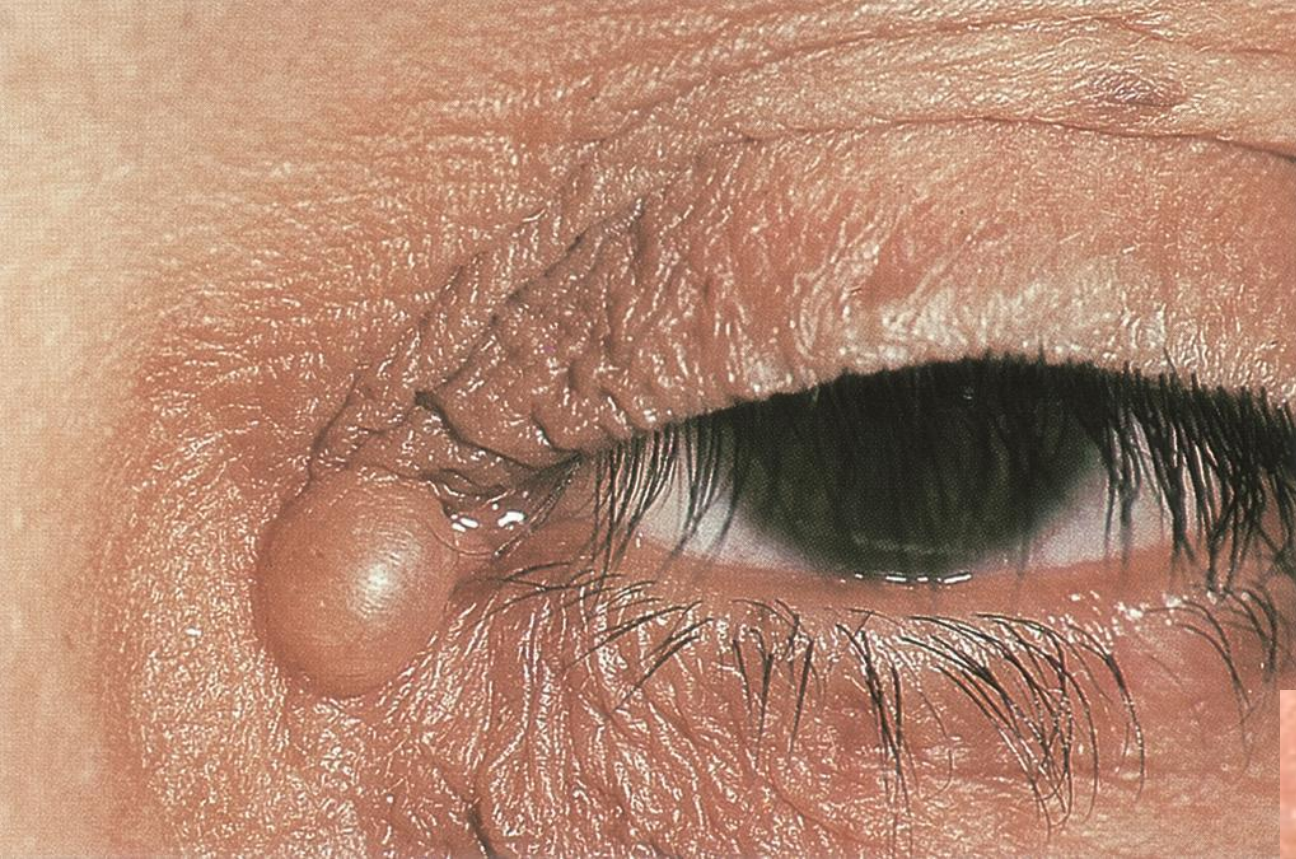- A variety of lesions that have a similar lobulated or pedunculated appearance
- Examples include seborrheic keratosis, viral papillomas, squamous papillomas, and viral warts



Epidermal inclusion cysts

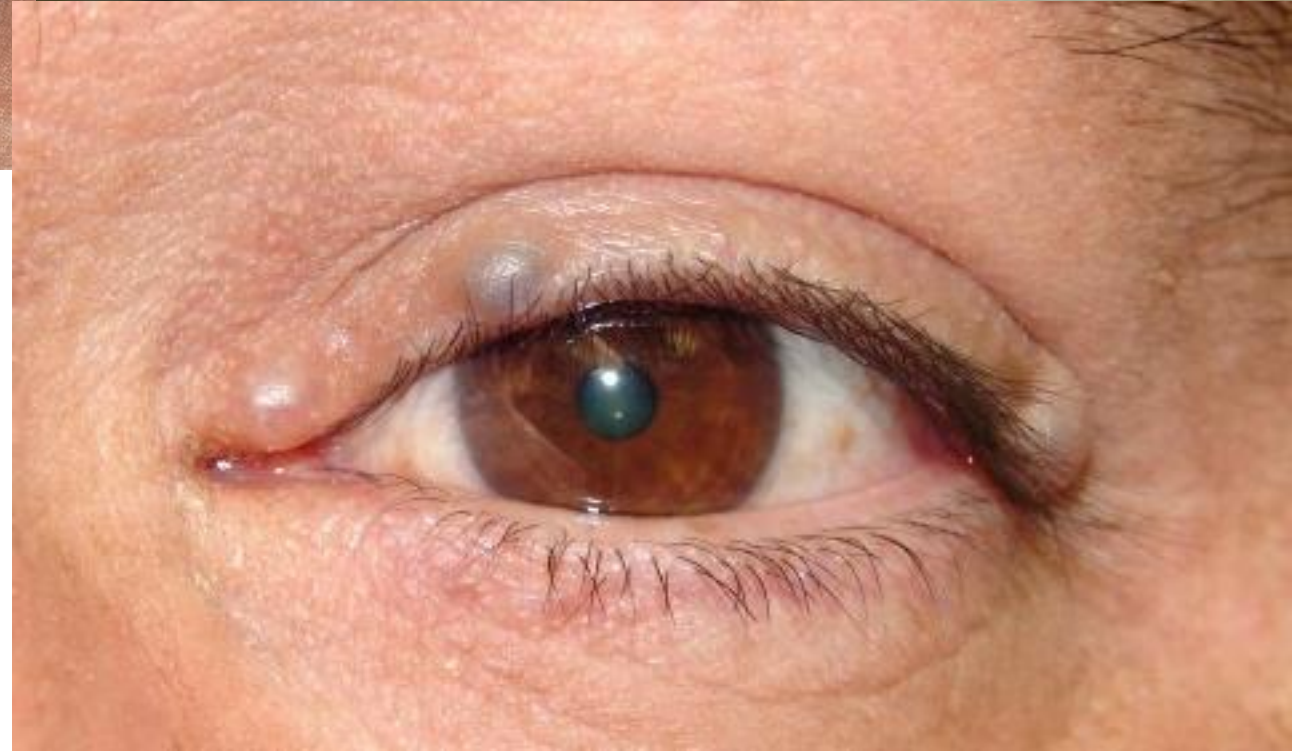- AKA Sebaceous cysts
- Contains keratin or sebum
- Presents as a slow-growing, elevated, round, smooth, white lesion





Apocrine Hidrocystoma

- Benign cystic tumor of the sweat glands.
- Presents as a translucent, solitary, asymptomatic, papule or nodule
- Remove cyst lining to avoid recurrence



Identify Contraindications

Lidocaine and epinephrine contraindications

Radiofrequency contraindication

- Pacemaker

Careful patient selection

- Uncooperative patients
- Keloid formation
- Lesions at the lid margin
- Risk of unsatisfactory cosmetic outcome



Photodocumentation

Facial photograph before and after procedure

- After photo can be immediately after or at 1-week follow-up

Concern about cell phone cameras

- Use a retired cell phone that is not connected to Google, Amazon, etc
- Move photos off camera to EMR



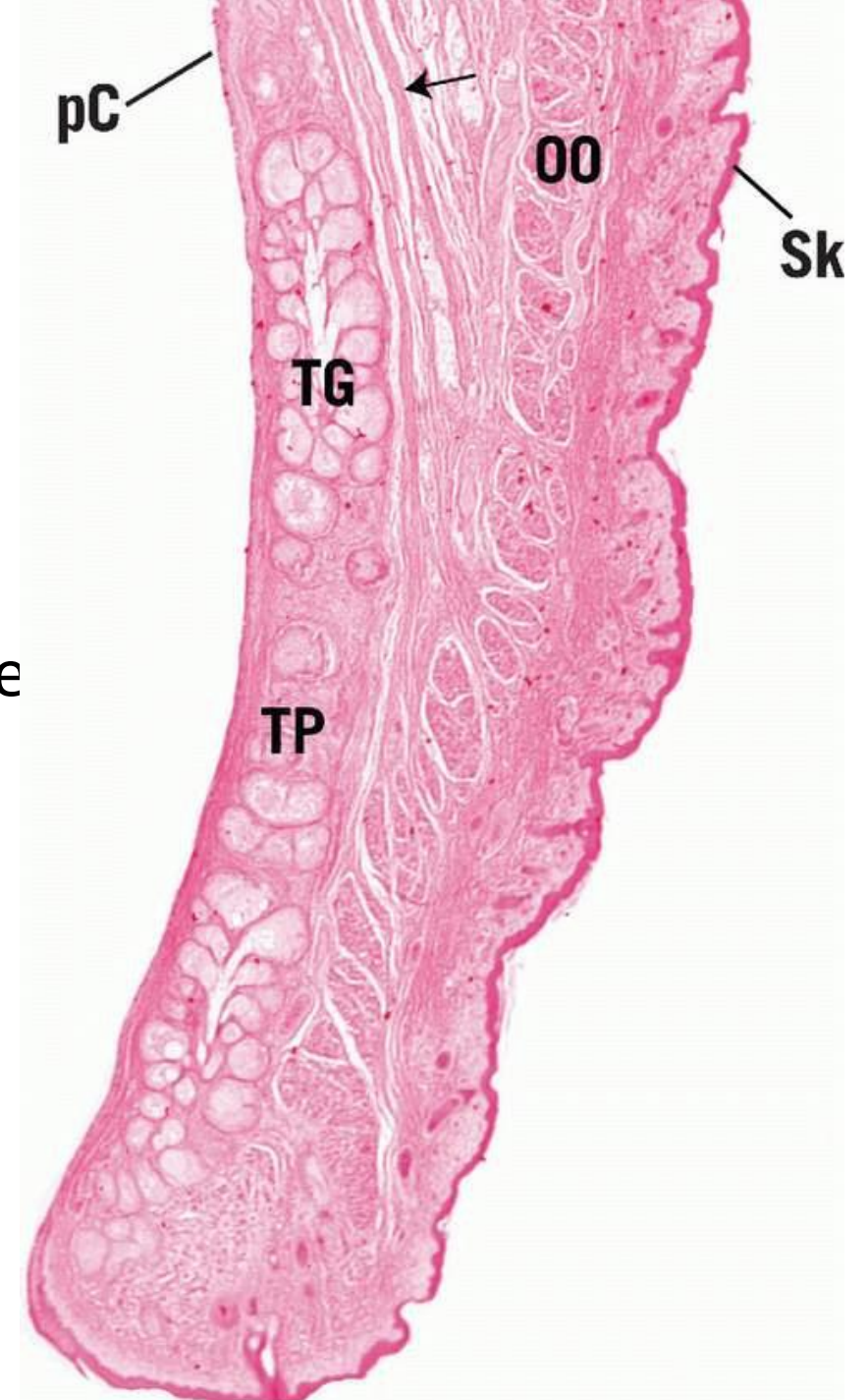
1. Classify lesion as benign or malignant
2. Identify contraindications
3. Informed consent
4. Photodocument the lesion (before and after)
5. Administer anesthesia
6. Perform the excision
7. Send specimen to pathology
8. Post-procedure care



Lesion Excision

Shave Biopsy

- **Remove superficial skin lesions in their entirety for histologic evaluation**
- Pedunculated lesions above the skin surface are particularly well suited for this removal technique
- **Horizontal slicing is performed at the level of the dermis**, avoiding injury to the subcutaneous tissues.
- Cosmetic results are generally good



Lesion Excision

Shave Biopsy Techniques

#15 Scalpel Blade

- Good choice for inexperienced physicians.

Scissors

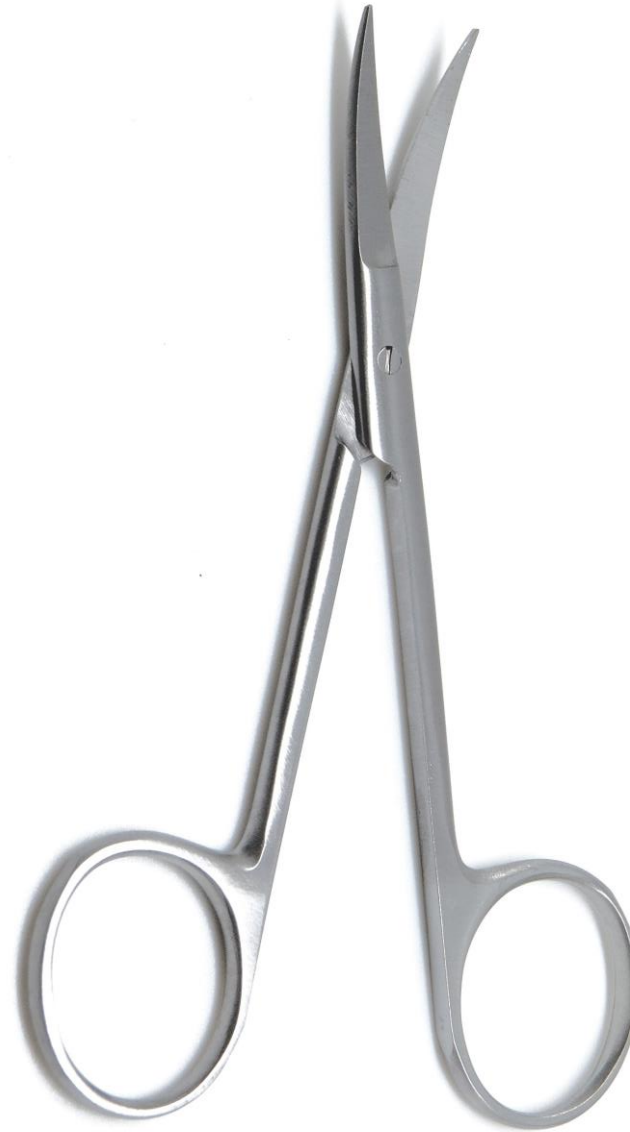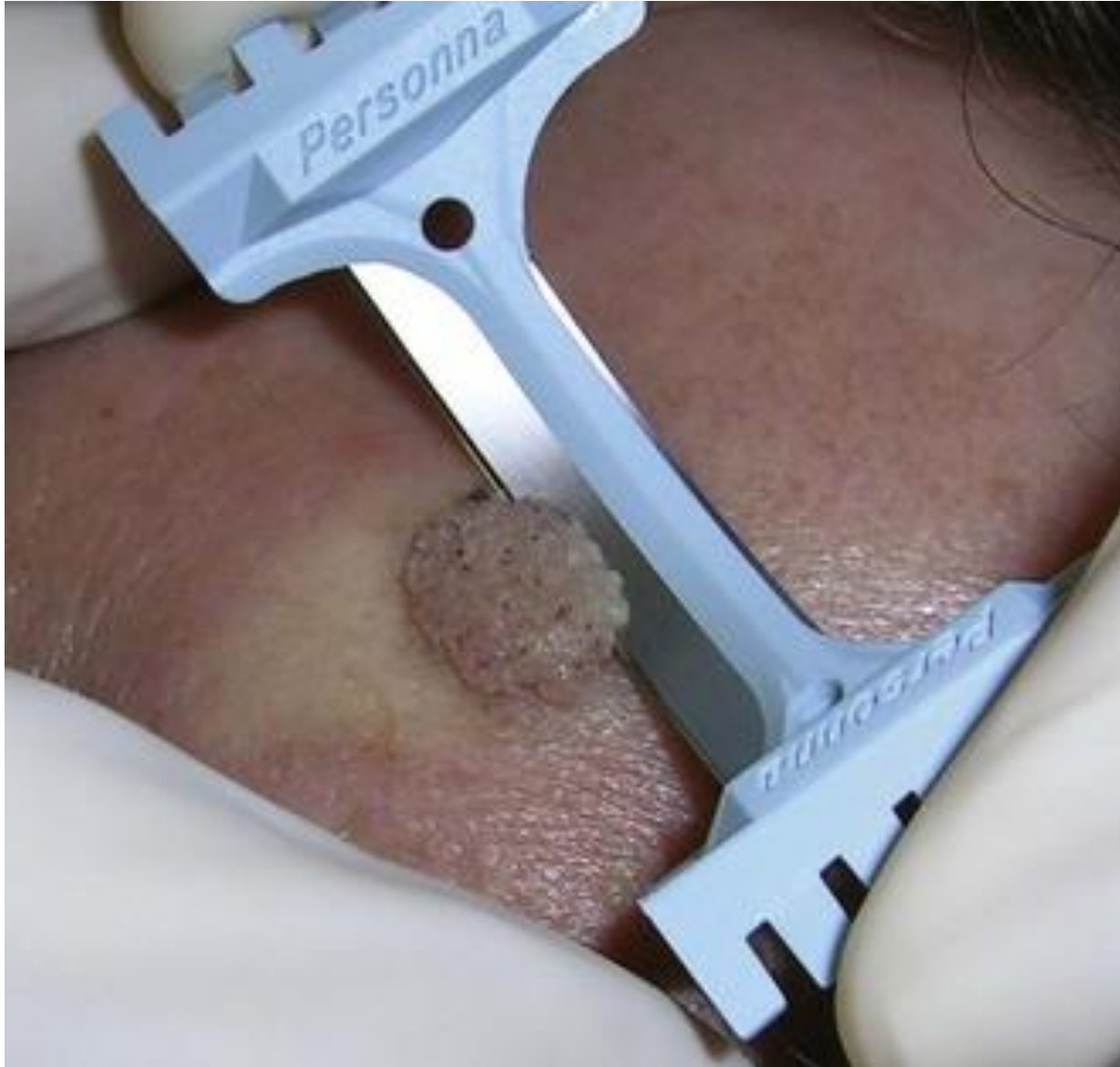- Good for elevated but not flat lesions.

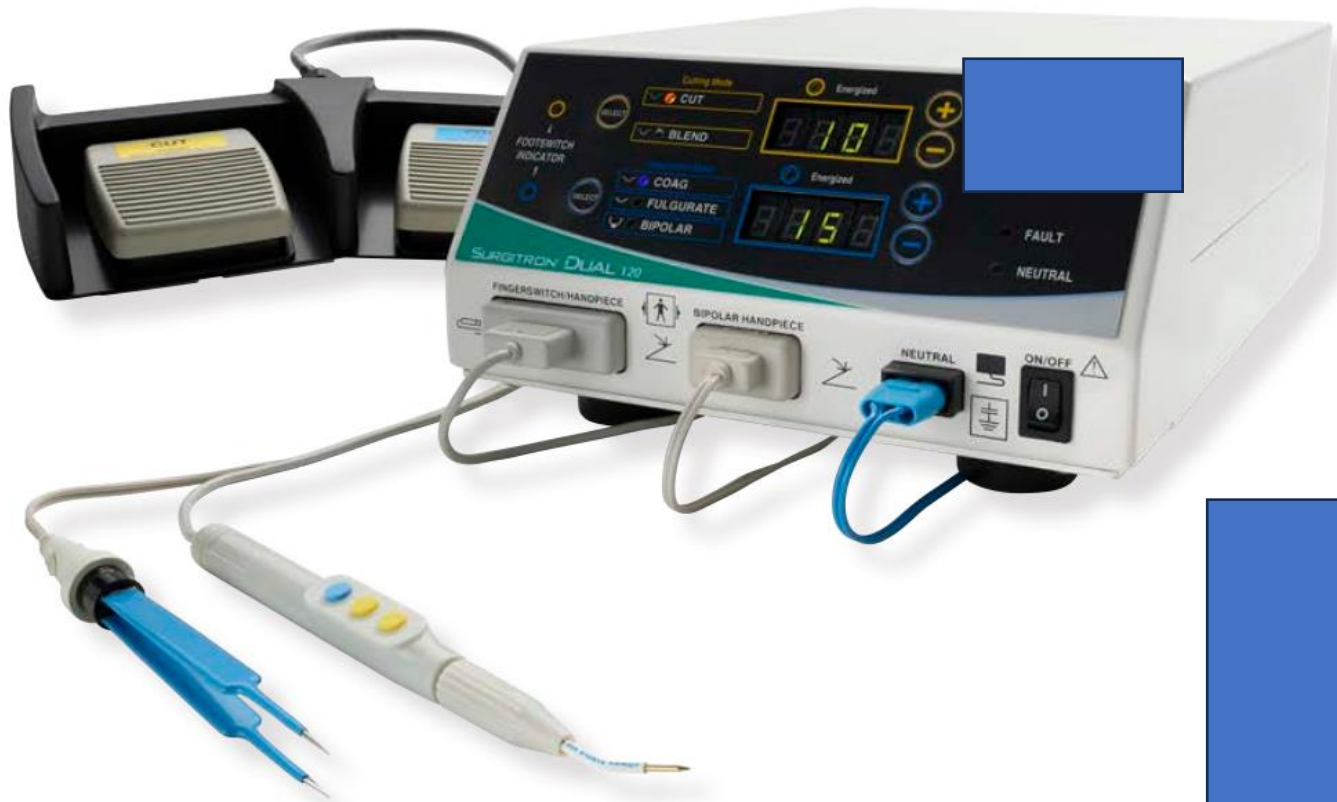
Flexed razor blade

- Classic method but potential for injury from the exposed blade.


Radiofrequency device

- Cuts and coagulates at same time. Rapid healing. Good cosmetic results










Radiofrequency Devices



Excision

- Diamond loop electrode 
- Round loop electrode 
- Blade electrode 



Fulguration/Desiccation

- Broad needle electrode 
- Needle electrode 


Coagulation

- Ball electrode 
- Bipolar forceps 

Incision

- Fine needle electrode 
- Vari-tip electrode 

Telangiectasia

- Luer-Lok needle adapter with 33-gauge metal needle 

Radiofrequency Papilloma Removal

Richard Trevino, OD

Lesion Excision

Complications

- Too deep an excision, causing excessive scarring
- Destruction of biopsied tissue for pathologic review
- Incomplete removal of a lesion
- Poor healing
- Scarring, hypopigmentation, or hyperpigmentation
- Recurrence of the lesion

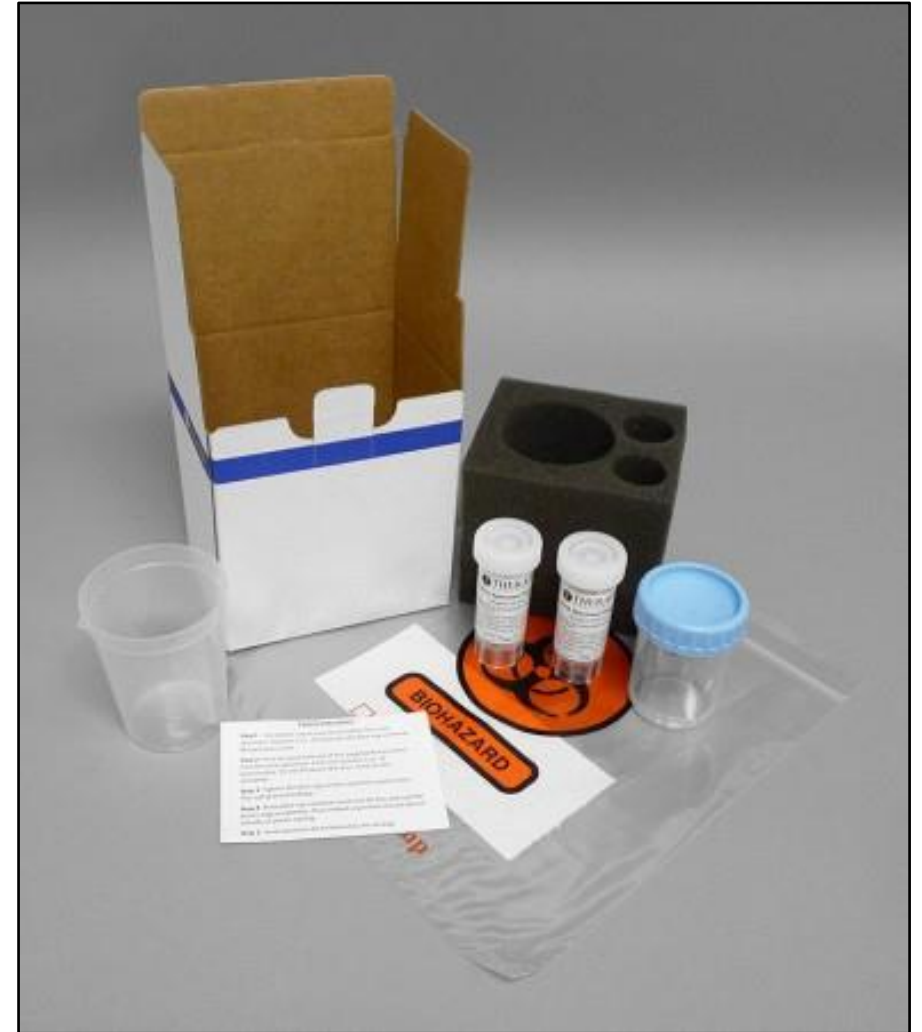

Surgeon
Error

Patient
Factors

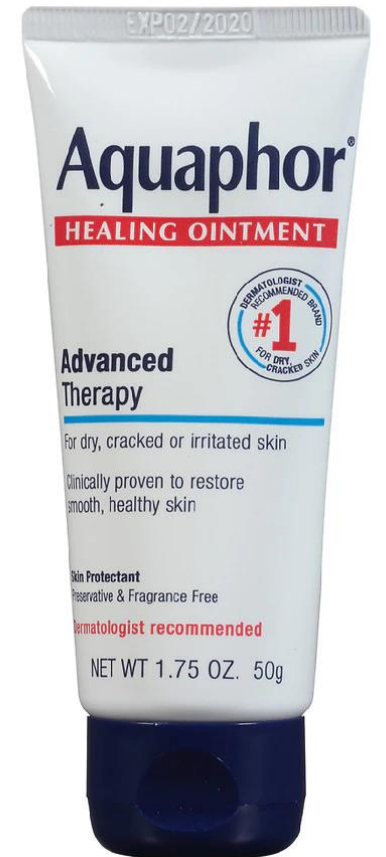Send Specimen to Pathology

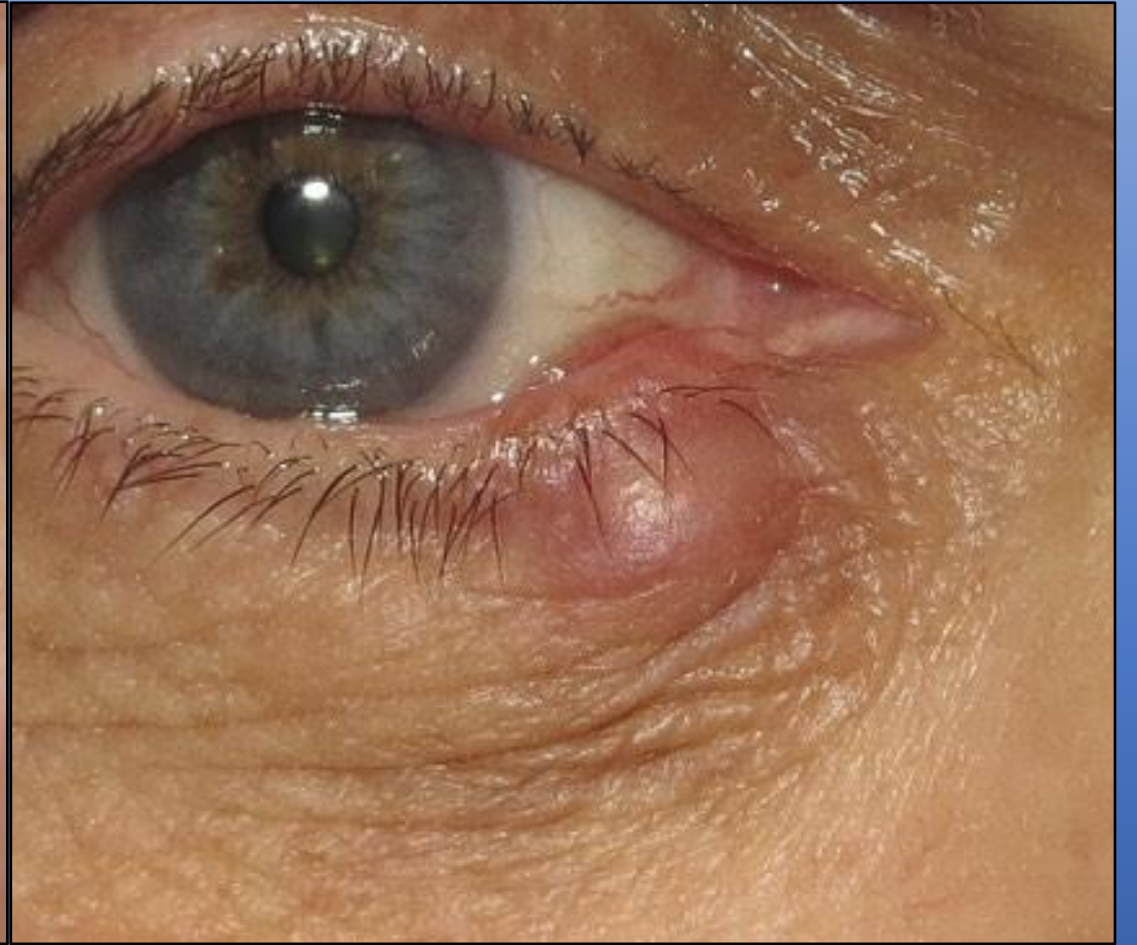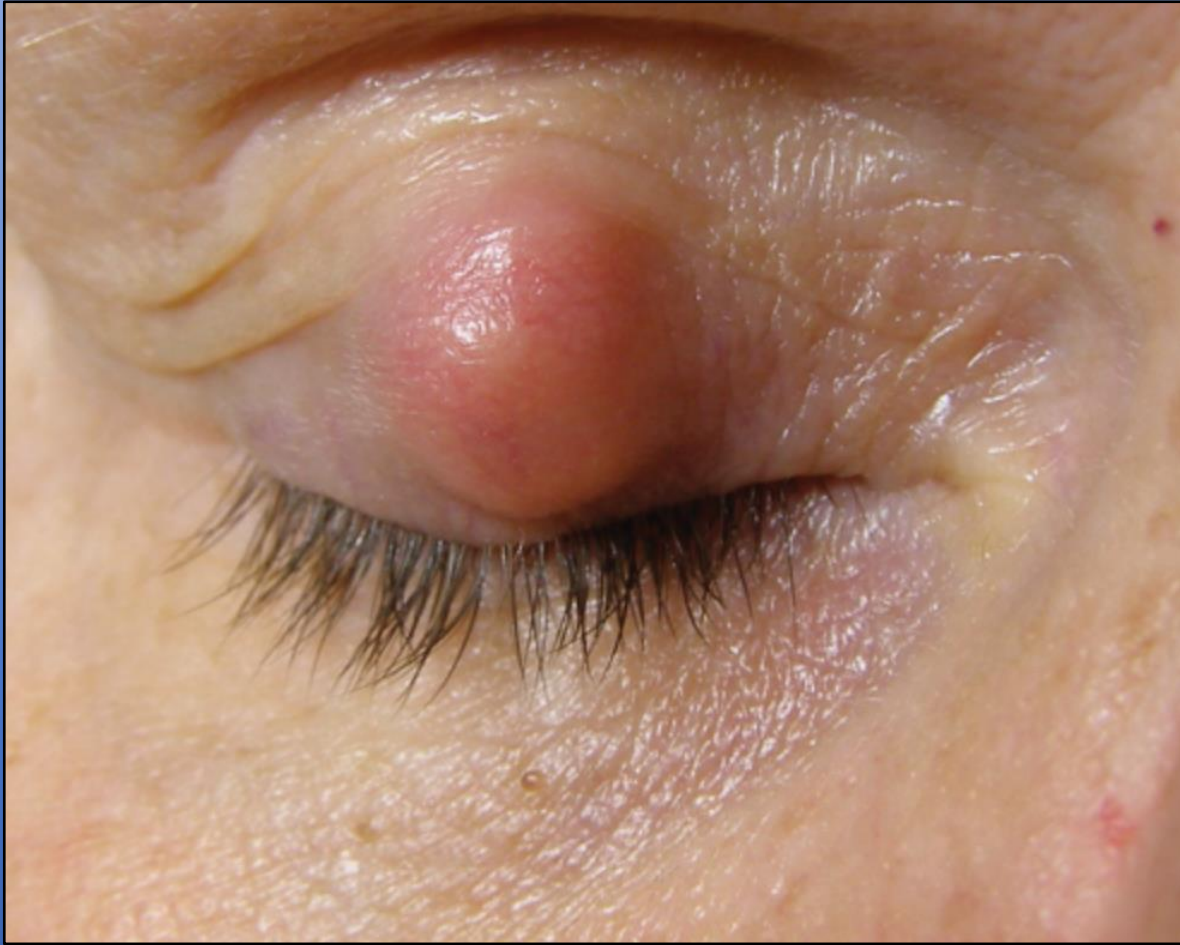- Labs typically provide specimen cups with formalin, requisition forms, and a tissue pick-up service.
- Provide pathologist with:
 - Relevant history and clinical background
 - Characteristics of lesion (location, elevated or flat, etc)
 - Your clinical diagnosis
- Patient's medical insurance is usually billed directly by the lab & pathologist.



Post-Procedure Care

- Apply antibiotic ointment
- Write procedure note
- **Moist healing and prevention of scab formation are essential to decrease likelihood of scarring**
- Wash treated area with soap and water QID
- Antibiotic (or bland) ointment PRN to keep the lesion moist
- A dressing is not needed except at bedtime to keep it moist
- After 7 days, the wound can be left untreated to heal





Chalazion Management

Differential Diagnosis

Chalazion

- A **sterile** lipogranuloma that develops around a meibomian or (less often) Zeis gland
- A chronic, nontender swollen mass at the margin or higher in the lid.

Hordeolum

- **Infection** of a meibomian (internal hordeolum) or Zeis (external hordeolum) gland.
- An acute, focal, painful, erythematous inflammation of the eyelid

Sebaceous cell carcinoma

Differential Diagnosis

Accuracy of clinical diagnosis of chalazion

- Many different benign, premalignant, and malignant conditions may clinically masquerade as a chalazion.
- **Sebaceous cell carcinoma** is the most often missed malignancy, followed by basal cell carcinoma
- Submission of all chalazion samples for histopathological evaluation is the best approach to avoid missing malignancies

STUDY	n	% Correct	% Benign	% Malignant
Ozdal (2004)	1060	93.6 %	4.8 %	1.6 %
Domarus (1976)	138	76.1 %	16.6 %	7.3 %
Hollwich (1976)	89	76.3 %	14.6 %	9.1 %

Table 1 Malignant and premalignant eyelid lesions clinically misdiagnosed as chalazion

<i>Histopathological diagnosis</i>	<i>Number of cases</i>	<i>%</i>
Sebaceous cell carcinoma	12	1.1
Basal cell carcinoma	3	0.3
Chronic inflammation with cellular atypia and mitotic figures	2	0.2
Total	17	1.6

Sebaceous cell carcinoma, an invasive malignant tumor of the eyelid, may frequently masquerade as chalazia (Ozdal, 2004)

Table 2 Benign eyelid lesions clinically misdiagnosed as chalazion

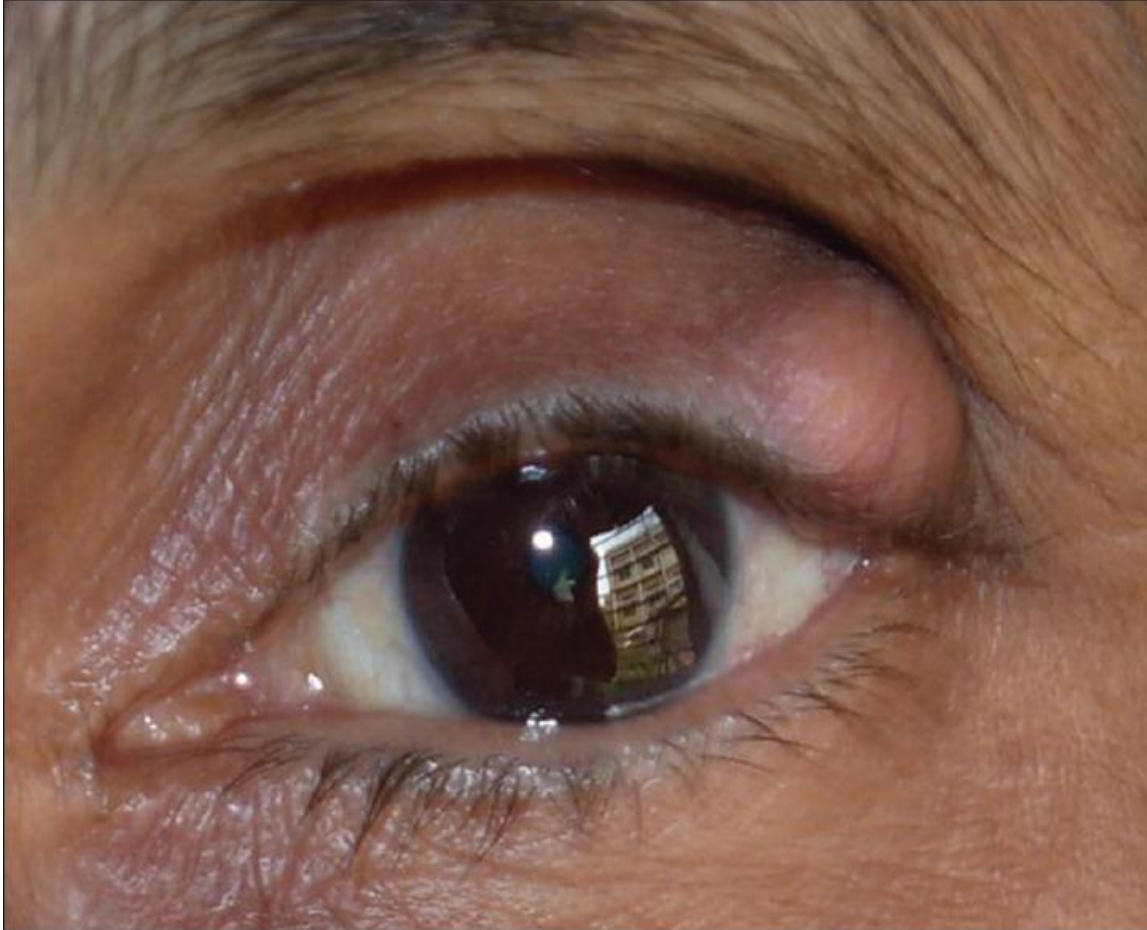
<i>Histopathological diagnosis</i>	<i>Number of cases</i>	<i>%</i>
Different types of chronic inflammation	24	2.2
Seborrheic keratosis	4	0.4
Epithelial inclusion cyst	4	0.4
Pyogenic granuloma	4	0.4
Papilloma	3	0.3
Sebaceous gland hyperplasia	3	0.3
Intradermal nevus	3	0.3
Inflammatory granulomatous foreign body reaction	3	0.3
Necrotizing granuloma	1	0.1
Dermatofibroma	1	0.1
Hydrocystoma	1	0.1
Total	51	4.8

Differential Diagnosis

Sebaceous Gland Carcinoma

- Arises from meibomian glands, Zeis glands, caruncle
- Third most common eyelid malignancy (after basal cell and squamous cell)
- Can masquerade as chalazion (nodular tumor) or blepharoconjunctivitis (spreading tumor)
- Risk factors: Females, older age, Asians
- Upper lid > lower lid, yellow in appearance
- **High index of suspicion whenever a chalazion recurs in same location**
- High incidence of metastasis (41%). Mortality rate second only to malignant melanoma
- The poor prognosis is associated with its ability to masquerade as other benign conditions, resulting in delayed diagnosis and treatment

Case report of sebaceous carcinoma masquerading as chalazion



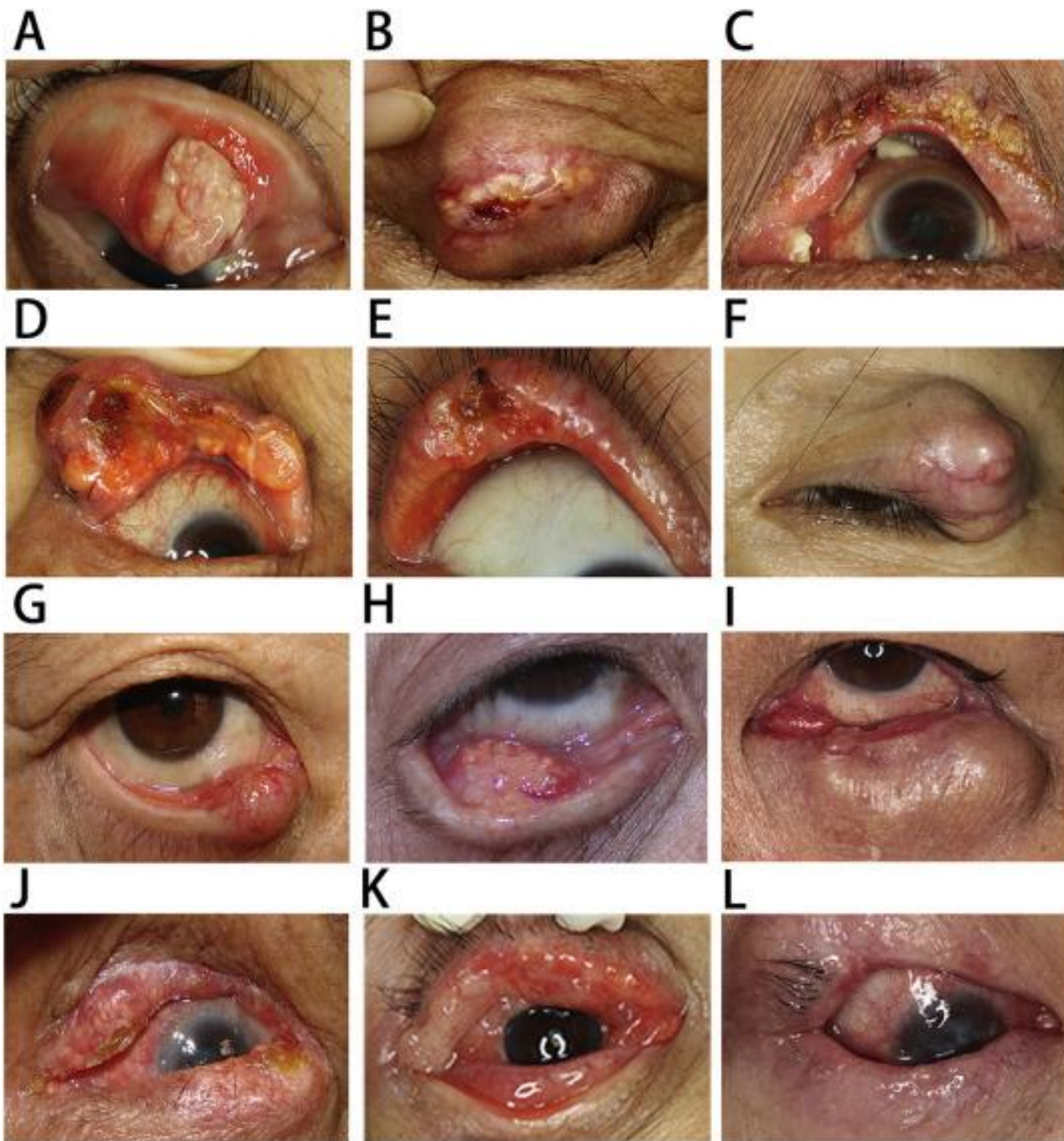
A 52-year-old woman presented with a well-defined nontender swelling of the left upper lid for 1 month.

She had a history of similar swelling 2 months back, and after a minor surgery, it was resolved.

Examination revealed a well-defined nontender, palpable nodule in the left upper eyelid of size 4 mm × 6 mm. The skin over the nodule was freely movable, not associated with blepharitis, meibomitis, thickening of the lid margin, or focal loss of eyelashes.

Initial plan of management was incision and curettage of the lesion. However, **during the procedure, the whole mass could not be adequately scooped**, so a part was incised and send for histopathological examination.

Histopathology revealed irregular lobular pattern, with each lobule containing disorderly admixture of basophilic sebaceous cells with variable amount of lipid in it. Marked nucleocytoplasmic pleomorphism was seen and was **diagnosed as sebaceous cell carcinoma**. (Sahu, 2021)



Clinical appearances in Chinese patients with eyelid sebaceous carcinoma (SC).

- (A) Solitary eyelid nodule arising from the meibomian glands of the upper eyelid.
- (B) Large ulcerated nodule.
- (C) Diffuse thickening of the upper eyelid with extensive loss of cilia.
- (D) Large nodule with large sunken ulceration of the upper tarsus.
- (E) Diffuse thickening of the upper eyelid with ulceration.
- (F) Large nodule causing ptosis.
- (G) Sebaceous carcinoma arising near the caruncle.
- (H) Nodular mass of the lower eyelid.
- (I) Large nodule of the lower eyelid with orbital involvement.
- (J) Multicentric nodules involving both eyelids and bulbar conjunctiva.
- (K) Recurrent fleshy mass in the medial upper palpebral conjunctiva presenting with pseudoinflammatory signs.
- (L) Extensive diffuse sebaceous carcinoma involving both eyelids, bulbar conjunctiva, and cornea pagetoid growth pattern. (Zhou, 2018)

Chalazion Treatment Options

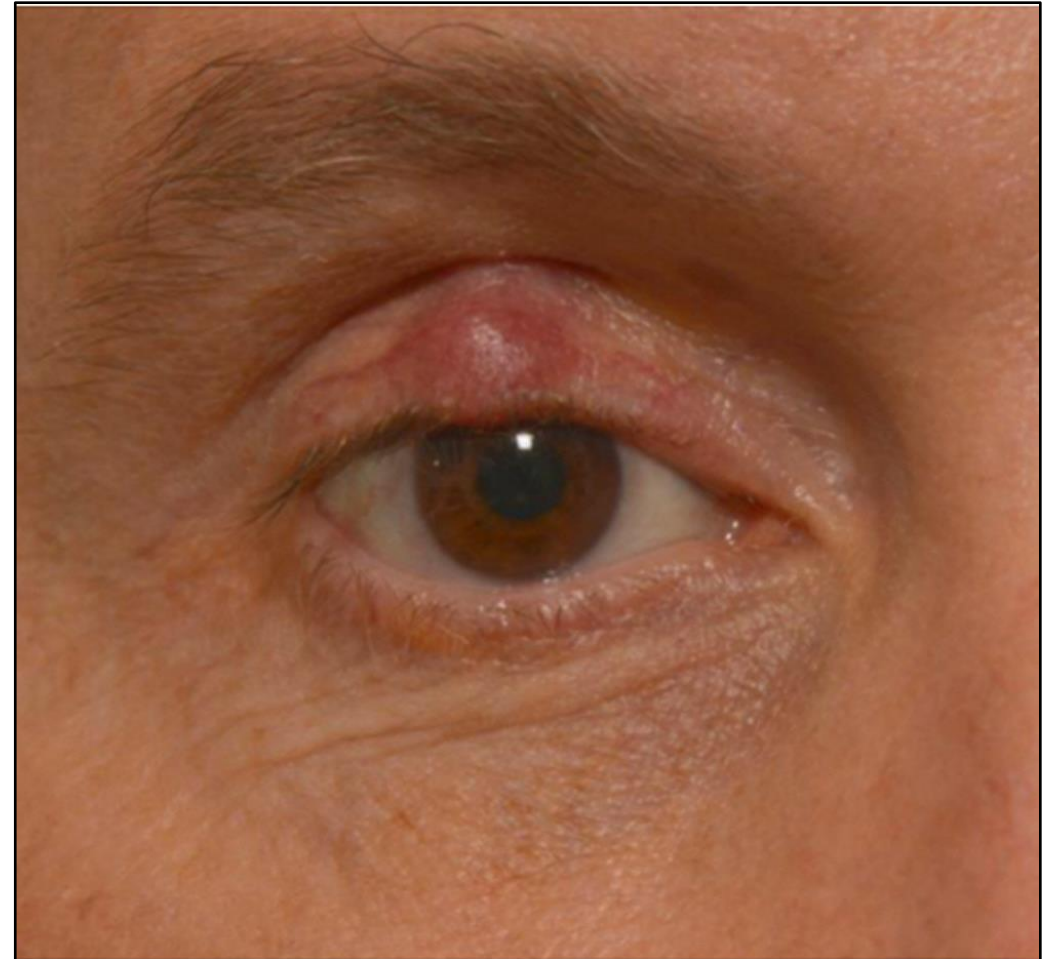Three treatment options

1. Conservative treatment

- Hot compresses and massage
- Adjunctive therapy
 - Topical or systemic antibiotics and steroids
 - Intensive pulsed light
 - Probiotics

2. Intralesional steroid injection

3. Incision and curettage



Intense Pulsed Light for Chalazion: A Single-Arm Prospective Cohort Study of 61 Patients

Qiu Yan¹, Zeyi Li¹, Zhuoyi Hu¹, Chang Cai¹, Dan Li¹

Affiliations + expand

PMID: 41733464 DOI: [10.1177/25785478261421408](https://doi.org/10.1177/25785478261421408)

Abstract

Objective: Chalazion is a common eyelid disorder with limitations in existing treatment options. While intense pulsed light (IPL) has shown potential in treating meibomian gland dysfunction, its efficacy for chalazion requires further validation. This study aimed to describe clinical outcomes after IPL for chalazion and to identify factors associated with lesion resolution.

Methods: This was a single-center, single-arm prospective cohort study. Sixty-one patients with chalazion were enrolled and received weekly IPL treatment. Follow-up was conducted 1 week after each session, and the primary outcome was assessed at the ≥ 1 -week visit after the final IPL session. Descriptive statistics, chi-square tests, and elastic net-penalized logistic regression were used to analyze treatment outcomes and associated factors.

Results: The overall lesion resolution rate after IPL treatment was 77.0% [47/61; 95% confidence interval (CI), 65.1-85.8%]. Chi-square analyses showed that symptom duration ($p < 0.001$) and the number of IPL sessions ($p = 0.002$) were significantly associated with lesion resolution. In Elastic Net-penalized logistic regression, compared with a single IPL session, two sessions [adjusted odds ratio (aOR) 3.685; 95% CI, 1.000-73.950] and ≥ 3 sessions [aOR 40.844; 95% CI, 1.897-247.637] were associated with higher odds of resolution. Compared with symptom duration > 30 days, symptom duration ≤ 7 days [aOR 21.101; 95% CI, 3.305-706.384] and 8-30 days [aOR 3.430; 95% CI, 1.000-57.852] was associated with higher odds of treatment success. Overall model performance was acceptable (fivefold cross-validated area under the curve = 0.887). No serious adverse events occurred.

Overall lesion resolution rate after IPL treatment was **77.0%**

Greater success for lesions present < 30 days

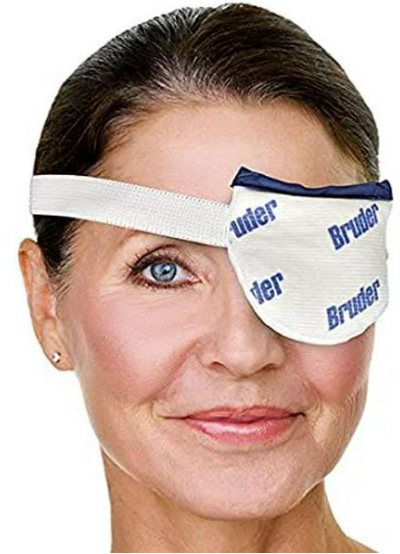Lesions that did not respond after first treatment session may respond after a second or third treatment

IPL treatment of chalazia is experimental and not covered by most insurance

Conservative Therapy

Conservative therapy includes:

1. **Warm compresses** should be applied to the affected lid for 10-15 minutes 2 - 4 times per day.
 2. **Massage** (either with fingers or cotton tips) to assist in the release of the chalazion contents.
 - Lid scrubs with baby shampoo can be an effective massage
- **Conservative treatment should be tried for at least 1 month.**
 - Success rate: Ranges widely from 25% to 87%
 - Dependent on patient education by the physician and patient compliance with the treatment regimen



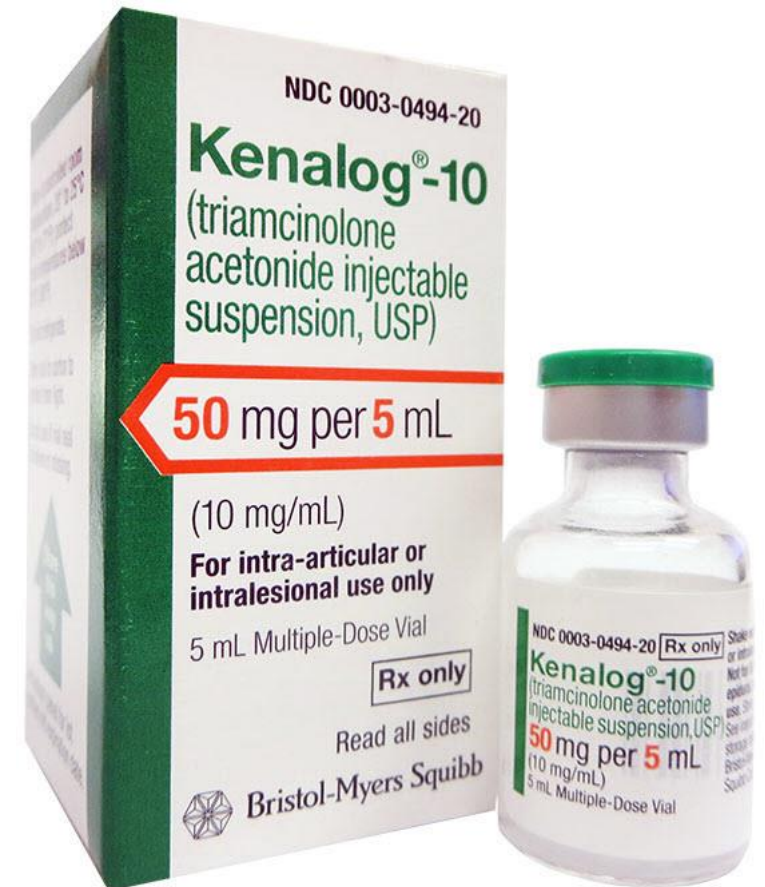Conservative Therapy Adjuvants

Antibiotics and steroids

- Although frequently prescribed, an antibiotic is unlikely to improve the resolution of a chalazion
- Antibiotics are believed to shorten the duration and severity of a hordeolum, although there is a paucity of evidence to support this
- Alsoudi (2022)
 - Review of over 2700 chalazion and hordeolum cases at a teaching hospital
 - 36.5% of cases were prescribed an antibiotic or antibiotic/steroid combo
 - **Antibiotics did not statistically improve the rate of resolution for either chalazia or hordeola**, regardless of whether prescribed as a topical and/or oral formulation.

Intralesional Steroid Injection

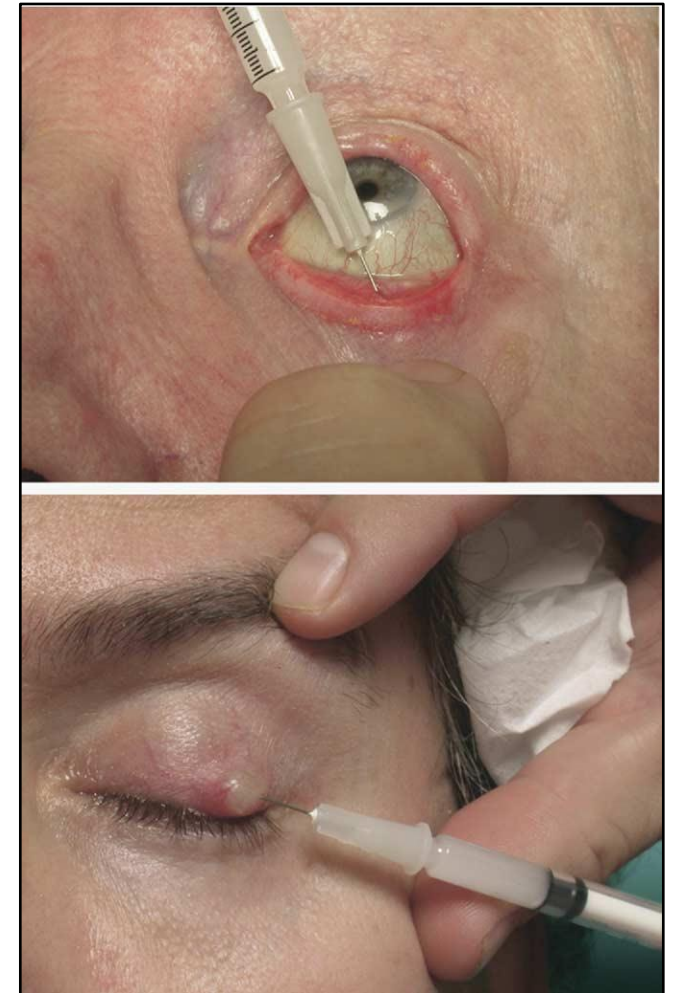
- Injection of triamcinolone acetonide (Kenalog) into the chalazion
- **Smaller lesions and those with more recent onset respond better to steroid injection** than larger and more long-standing lesions
- Talley (2013) – Rule of Six
 - From his personal experience
 - If the chalazion is <6mm and/or has been there <6mos, there is a 60% chance that it will resolve with steroid injection



Intralesional Steroid Injection

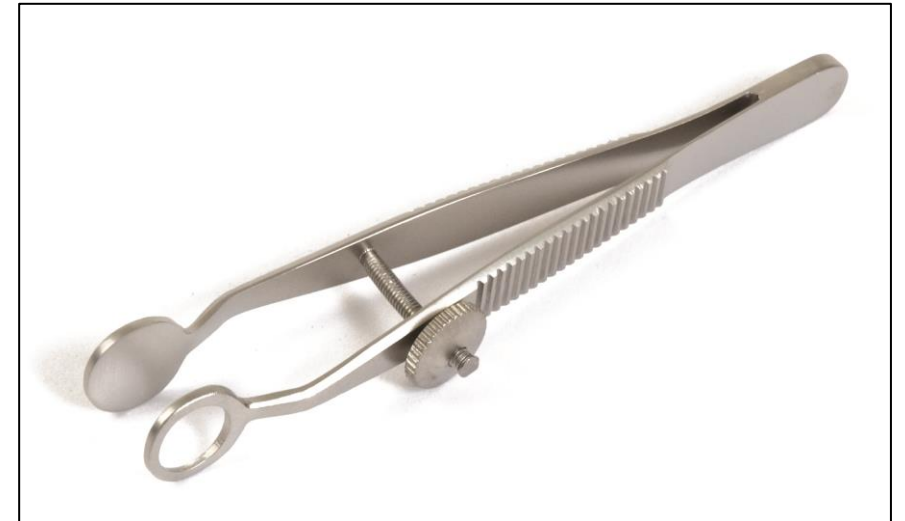Transcutaneous vs Transconjunctival

- Injection through the skin is less painful, but is associated with risk of **skin depigmentation**, especially in more heavily pigmented individuals
- Transconjunctival injection is more challenging in young children and poorly cooperative patients, but minimizes depigmentation risk
- **Recommend using a transconjunctival approach unless the patient cannot tolerate it**



Intralesional Steroid Injection – Procedure

1. Obtain informed consent
2. Instill topical anesthetic
3. Prepare syringe
 - No study has compared different doses and concentrations of TA.
 - Recommend using 0.2 ml of 10 mg/ml TA
4. **Apply chalazion clamp and evert lid**
 - Use of a clamp is optional, but it avoids risk of inadvertent globe perforation
 - **Accidental globe penetration has been reported as a result of injection of steroid into a chalazion.**



Intralesional Steroid Injection – Procedure

5. Apply topical lidocaine to conjunctival surface of chalazion
 - Optional: To minimize the discomfort of transconjunctival injection
- 6. Insert needle directly into chalazion and inject steroid**
 - It is sometimes necessary to inject into the immediately adjacent subconjunctival space if the lesion is very dense
7. Remove clamp
8. Instill topical antibiotic ointment
9. Schedule return visit in 2 weeks
 - **A second injection may be performed at this visit, if needed**

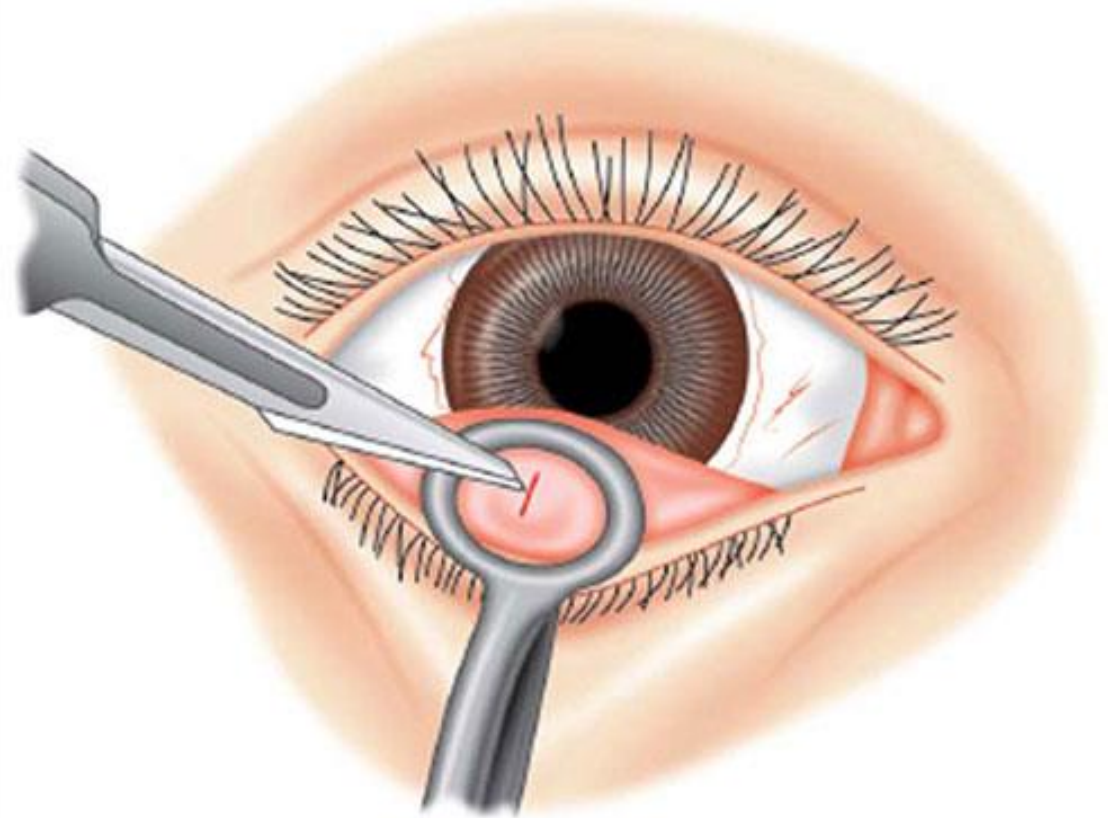
Intralesional Steroid Injection

Complications

- **Failure to respond**
 - Common. Success rate varies with size and age of lesion
- Depigmentation
 - Rare. More common with transcutaneous route and heavy pigmentation
- **Subcutaneous yellow/white deposits**
 - Common. Steroid precipitates in the tissue. Will spontaneously resolve with time
- Fat atrophy
 - Rare. Periorbital fat atrophy may occur in conjunction with depigmentation
- Globe perforation
 - Rare, accidental. Use chalazion clamp to avoid
- Glaucoma
 - Rare, may be more common with preexisting glaucoma or OHT

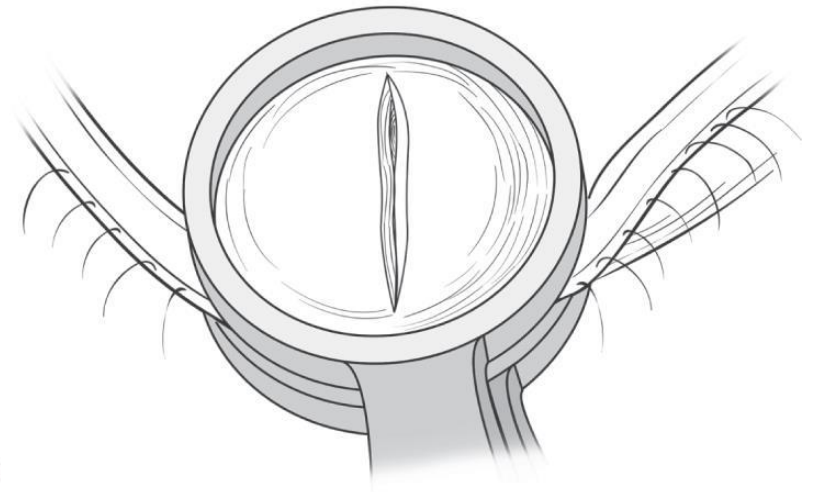
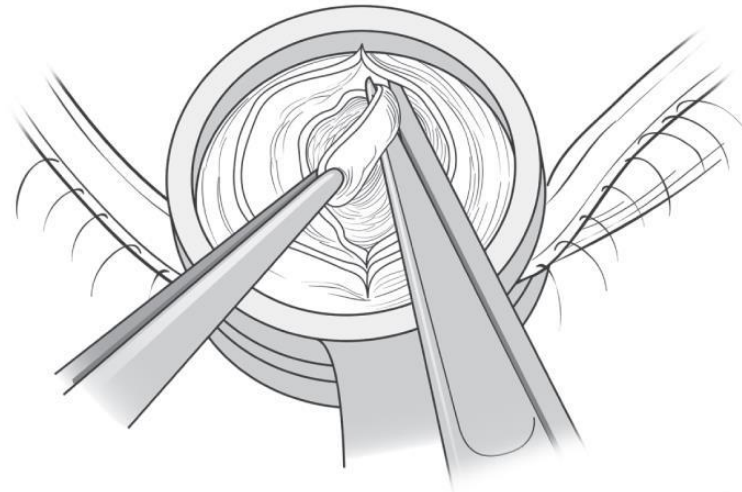
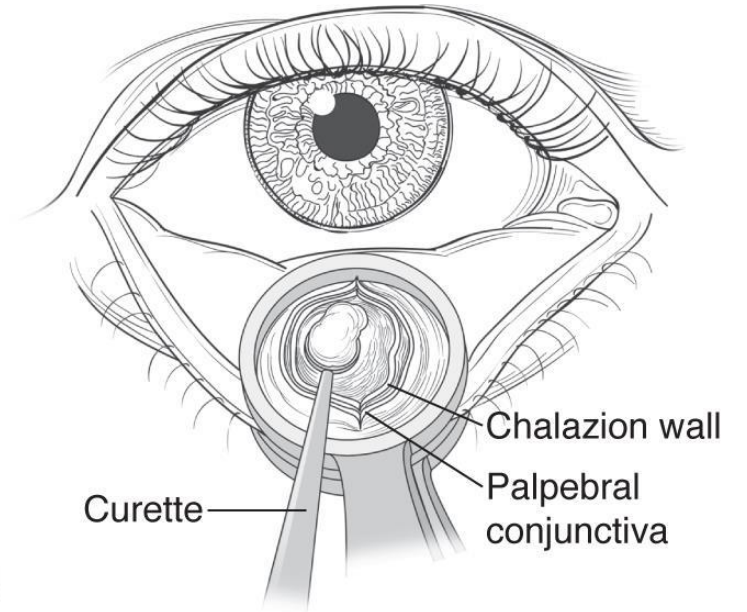
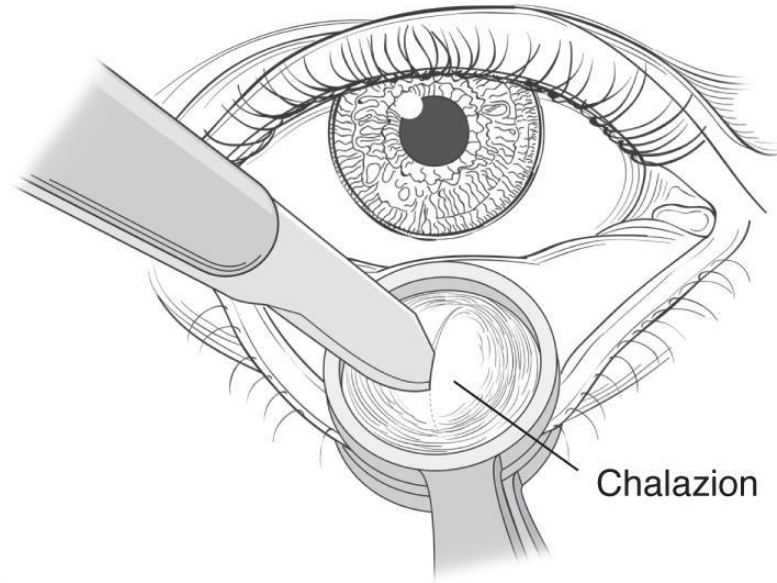
Incision and Curettage

- Surgical debulking of the chalazion
- The “**gold standard**” treatment of chalazia
- Higher success rate than other treatment options
- Failure to remove the entire lesion, including the **pseudocapsule** that surrounds the lesion, will increase risk of recurrence.



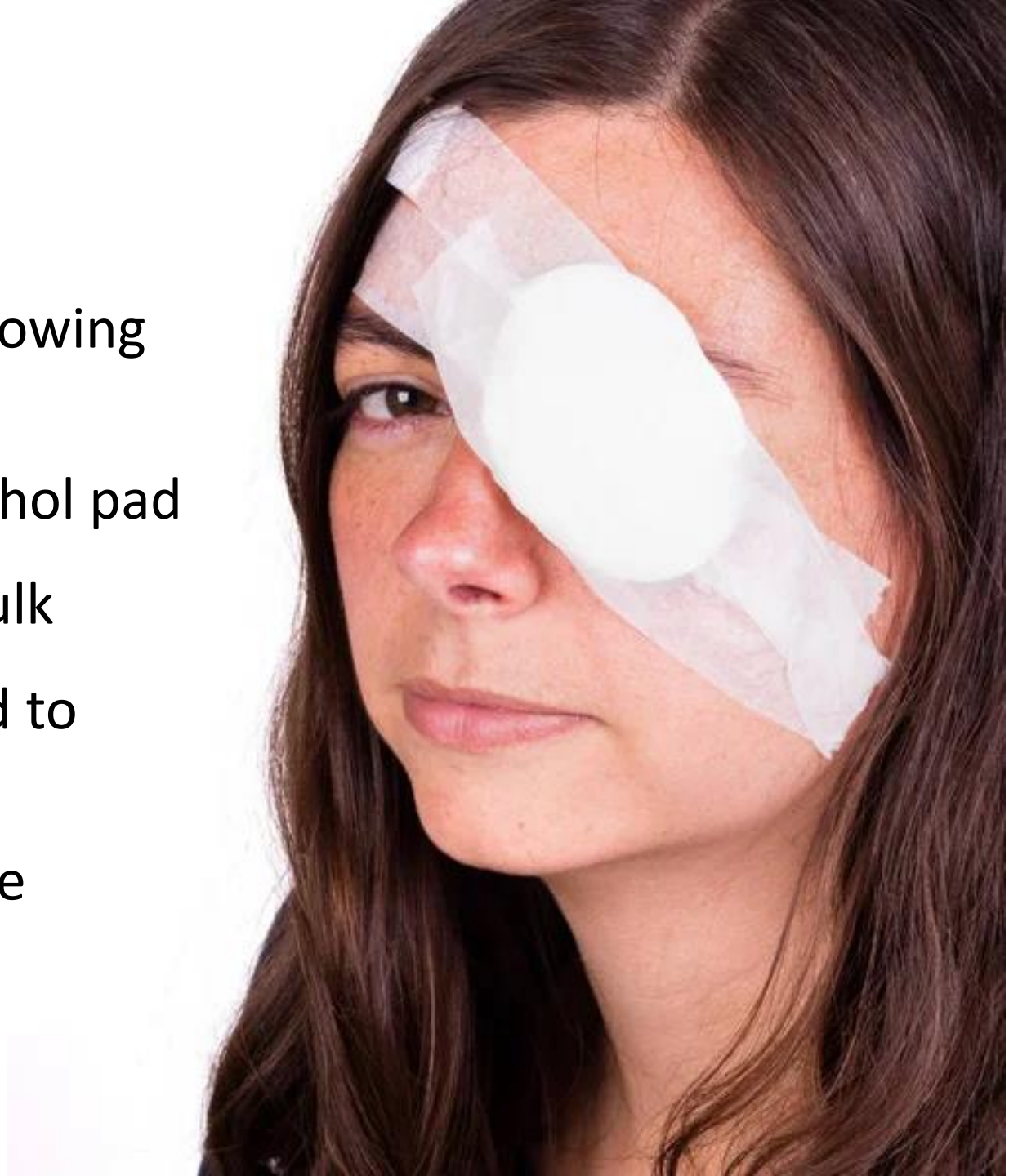Chalazion I&C Procedure

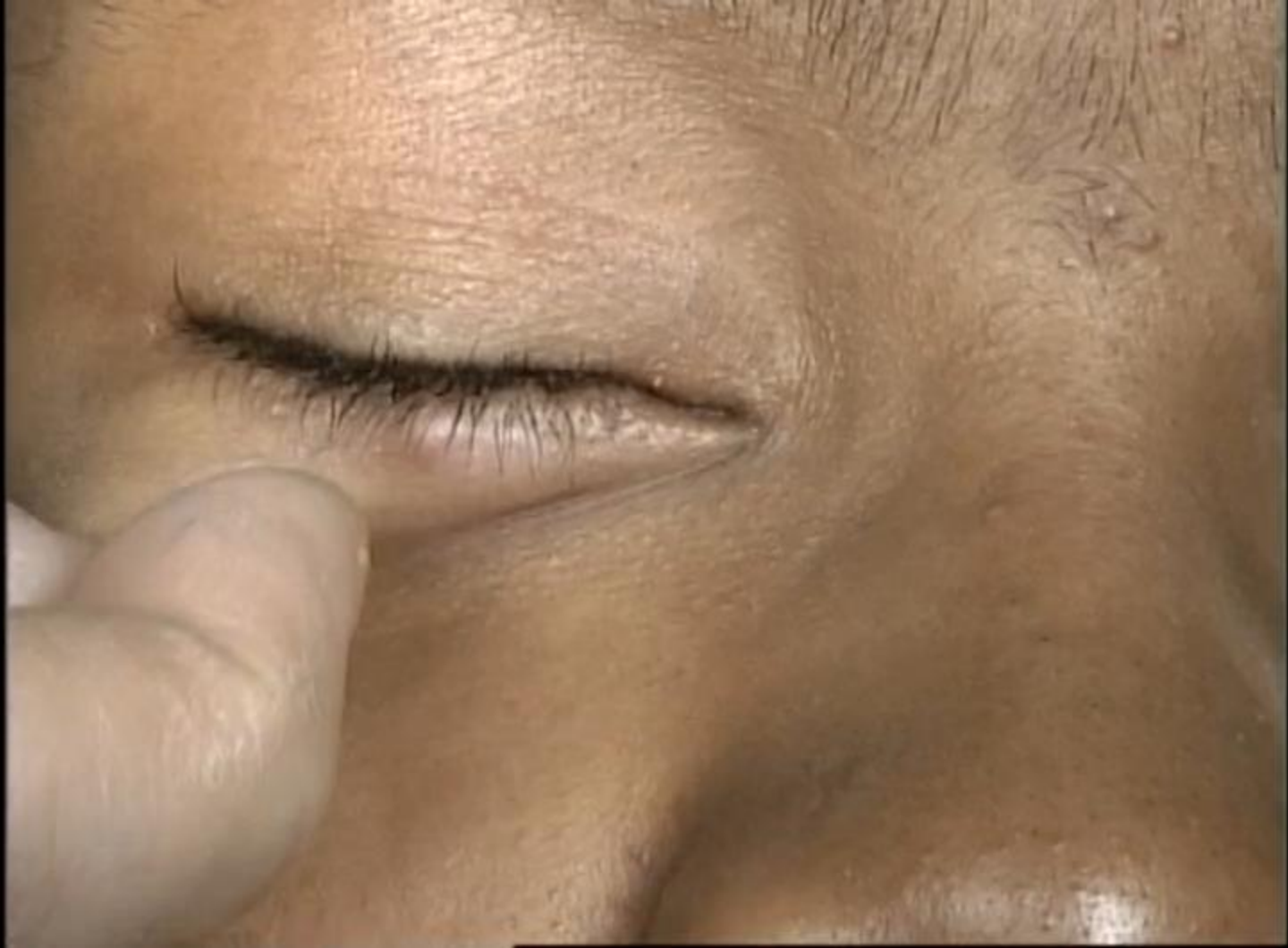1. Informed consent
2. Anesthesia
3. Povidone iodine 5% x 3 min
4. Apply clamp
5. Incise lesion with scalpel **A**
6. Debulk with curette
7. Excise pseudocapsule
8. Remove clamp
9. Pressure patch x 4hrs
10. Rx antibiotic ung x 1 week
11. RTC 2 weeks



Pressure Patching

- Decreases risk of “bloody tears” following procedure
- Clean forehead and cheek with alcohol pad
- Use 2 oval eye pads for adequate bulk
- Apply 3 strips of tape from forehead to angle of jaw
- Apply sufficient pressure to keep eye closed under patch
- Pt removes after 4 hours





Incision and Curettage

Complications

- Infection
 - Rare. Post-op antibiotic ointment x 1 week prophylaxis
- **Hemorrhage**
 - Common. Post-op pressure patching x 4 hours. D/C anticoagulants 24 hrs rarely indicated. Only do so after consultation with prescribing physician
- **Persistent/Recurrent chalazion**
 - Common. Palpate to confirm complete lesion removal. Pseudocapsule excision
- Canalicular trauma
 - Rare/Accidental. Use caution with medial lesions. Consider steroid injection
- Globe perforation
 - Rare/Accidental. Use caution while injecting anesthetic into lid

Comparison of Chalazion Treatment Options

Aycinena (2016)

- Meta-analysis of success rate and complications of I&C vs steroid injection (SI)
- **I&C may be more effective than a single steroid injection**
- No difference in incidence of complications

Study	I&C	SI	Weight	Risk Ratio	
	Events /total	Events /total		Random	95% CI
Ahmad	59/75	41/66	16.4%	0.79	[0.63, 0.99]
Ben Simon	33/42	42/52	16.7%	1.03	[0.84, 1.26]
Biuk	12/15	13/15	14.5%	1.08	[0.79, 1.49]
Goawalla	39/45	47/56	17.4%	0.97	[0.82, 1.14]
Jacobs	12/20	2/23	3.0%	0.14	[0.04, 0.57]
Khurana	23/25	11/25	11.7%	0.48	[0.30, 0.76]
Mustafa	9/12	9/12	11.6%	1.00	[0.63, 1.59]
Watson	19/30	9/39	8.7%	0.36	[0.19, 0.69]
Total (95% CI)	206/264	174/288	100%	0.77	[0.60, 1.00]

Favors I&C Favors SI

Comparison of Chalazion Treatment Options

Advantages of I&C

- Higher success rate than steroid injection
- Can be used in infected chalazia
- Used when biopsy is indicated
- Recommended for larger lesions

Disadvantages of I&C

- Requires more equipment and expertise
- Longer recovery time
- More pain and inconvenience
- Risk of adverse events such as bleeding, lacrimal puncta scarring, and loss of functionality

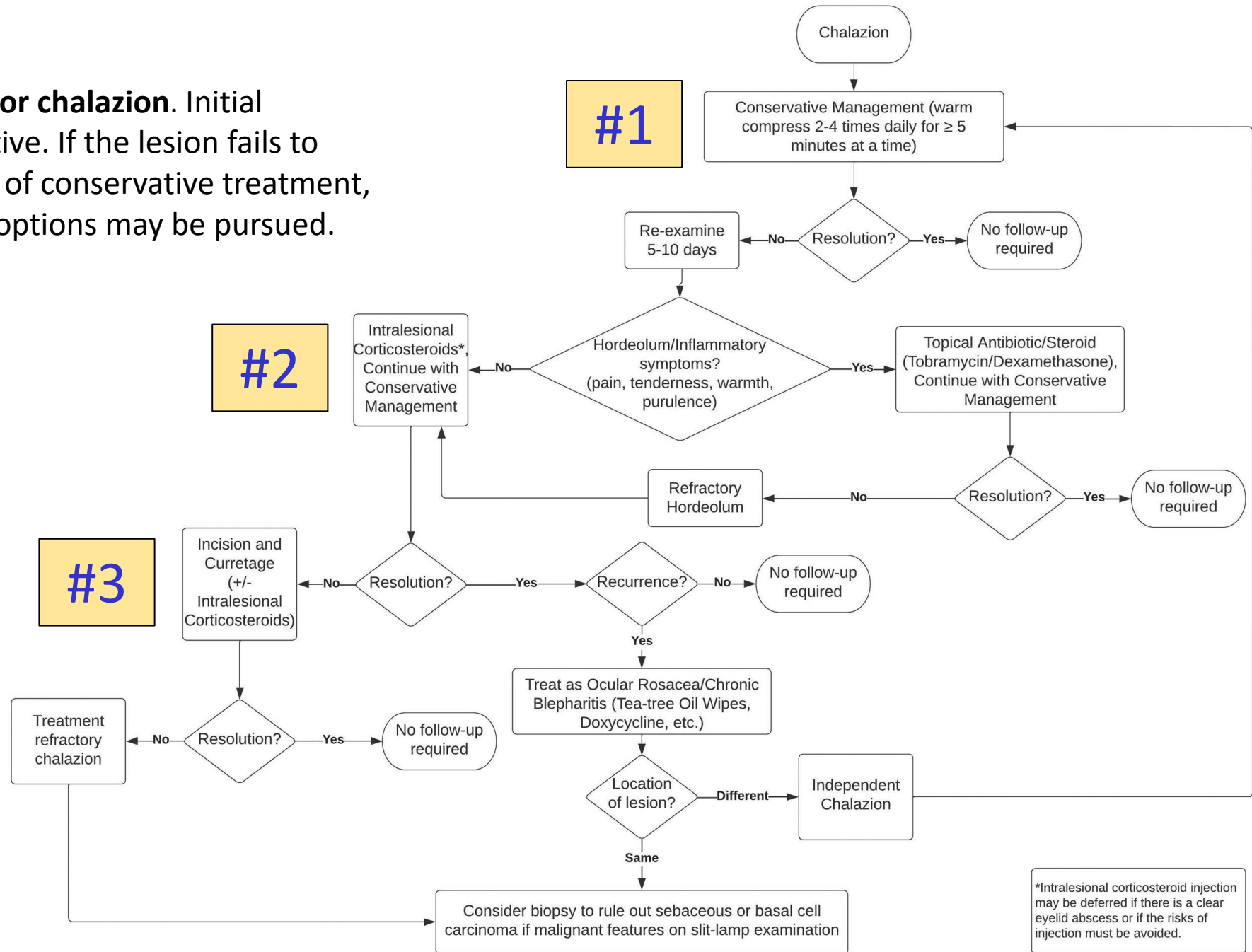
Advantages of Steroid Injection

- Quick procedure with fast recovery time
- Less equipment needed and less expensive
- Less pain during and after the procedure.
- Recommended for multiple and marginal chalazia
- Recommended for lesions close to the lacrimal drainage system

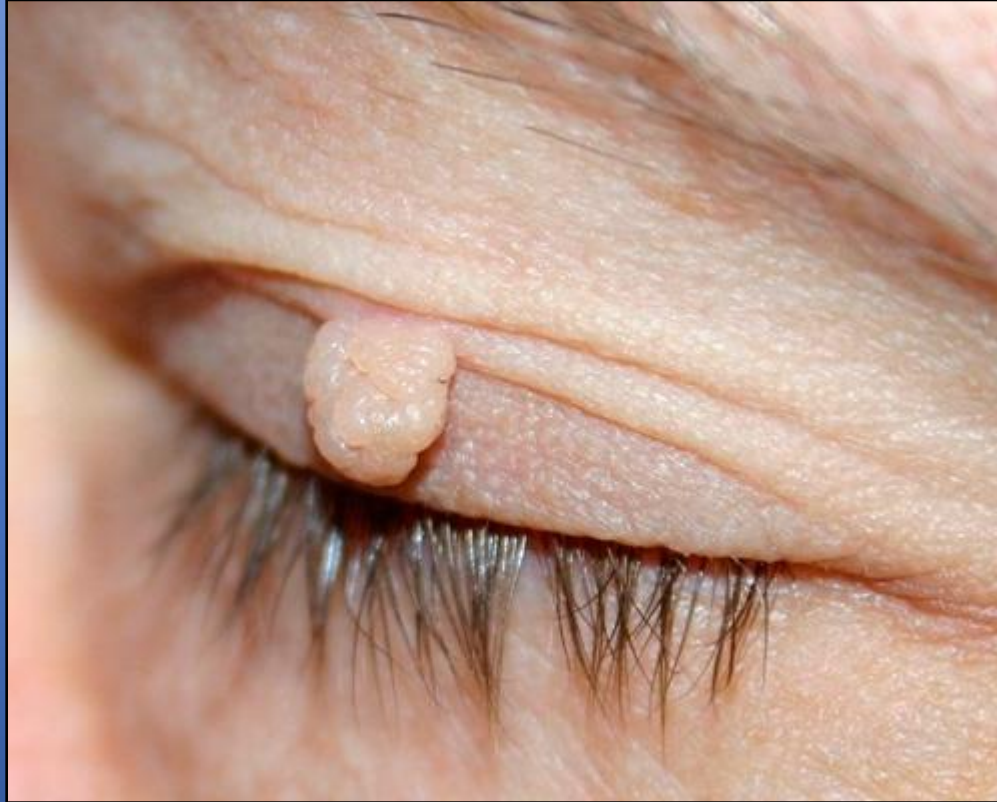Disadvantages of Steroid Injection

- May require multiple injections
- May delay diagnosis of sebaceous cell
- Risk of depigmentation and fat atrophy, IOP elevation, and globe perforation

Treatment algorithm for chalazion. Initial treatment is conservative. If the lesion fails to respond after 4 weeks of conservative treatment, then other treatment options may be pursued. (Kim, 2022)

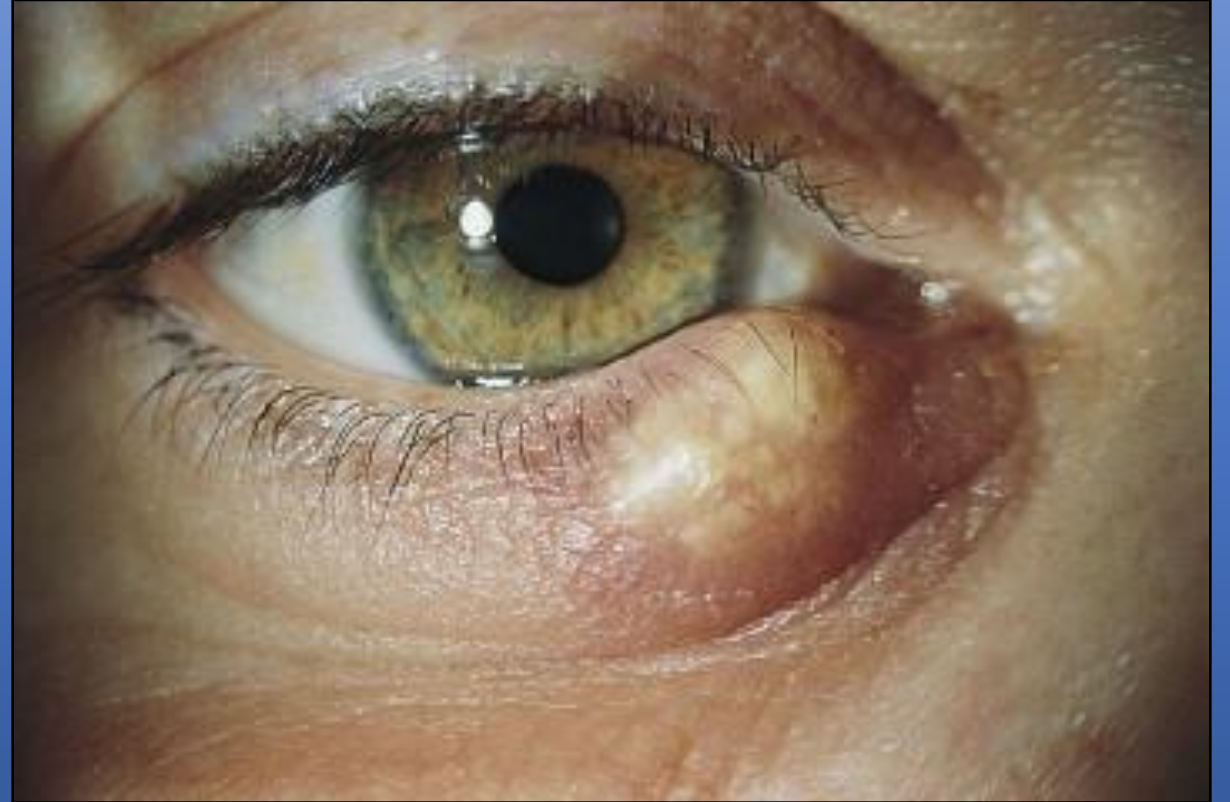


Minor Surgical Procedures



Benign Skin Lesions

CPT 11440 (\$100)



Chalazion Management

CPT 11900 (\$60); CPT 67800 (\$120)

Thank You!

rctrevin@iu.edu

richardtrevino.net

